The Journal of International Medical Sciences Academy
2018 ; (January – March); Vol 31; No. 1

ORIGINAL ARTICLE

Imaging Spectrum of Posterior Cranial Fossa Pathologies: A Pictorial Essay.

Hameed Arafath , B. Mallikarjunappa, Shaik Sadiq, Manju Bhargavi, Ramesh Kumar

Department of Radio-diagnosis, PESIMSR, Kuppam, Andhra Pradesh, India

ABSTRACT

Introduction Posterior cranial fossa is a space in the skull containing principal organs like cerebellum and brain stem [Mid brain, pons and medulla]. Cerebellum is a vital structure of the brain and it's dysfunction results in in-coordination of movements, dysarthria, dysmetria etc. Brain stem contains majority of cranial nerve nuclei and their connections. Most of the varied pathologies are in cerebellum and brain stem. Mid brain having vascular pathologies as a routine pathology.

We share our experience in a rural medical college - The incidence and imaging features on USG, CT and MRI of various common cerebellar pathologies like congenital cerebellar malformations, vascular pathologies, infective, inflammatory conditions and neoplastic lesions which must be known to all radiologists, neurologists and neuro surgeons for their prompt diagnosis and management.

Materials and Methods We have described the posterior fossa pathologies from June 2017 to 5th Oct 2018, their imaging features by using USG SAMSUNG HS 70 A, CT – Elite bright speed, MRI – GE Signa explorer 1.5T. We have described the following posterior cranial fossa pathologies like, Congenital malformations like cerebellar hypoplasia, ACM, MCM, DWM, Occipital Encephalocele, Arachnoid Cyst, Cerebellar Vascular Pathologies like PICA Infarct, Wallenburg Syndrome, PRES, Hemorrhage, Infective and Inflammatory Conditions like Tuberculoma, Intraventricular Neurocysticercosis, Fahr's Disease, Intra and Extra Axial Posterior Cranial Fossa Masses like, Pilocytic Astrocytoma, Medulloblastoma and Common Extraaxial CP Angle Tumours.

Conclusion It is important to know as a Radiologist, The Anatomy, Various Commonest Pathological Entities, Their Imaging features to facilitate early correct diagnosis or significantly to narrow the working differential diagnosis.

Key Words: **DWM** – Dandy Walker Malformation, **ACM** – Arnold Chiari Malformation, **MCM** – Mega-Cisterna Magna, **PRES** – Posterior Reversible Encephalopathy Syndrome, **CP Angle** – Cerebello Pontine Angle, **PICA** - Posterior Inferior Cerebellar Artery, **PCF** - Posterior Cranial Fossa

Introduction

There is a significant advances in pre and postnatal neuro imaging, MDCT and MRI were lead to understanding the accurate definition, classification of congenital posterior fossa malformations, vascular pathologies and characterising the intra and extra axial masses of the posterior cranial fossa.

Materials and Methods

Our study was a prospective study of pts referred to our dept from pediatrics, OB&G , Departments of Medicine , Surgery and Neurology from June 2017 to 5th October 2018, of posterior cranial fossa lesions of congenital and acquired. The relevent clinical, radiological findings of congenital and acquired malformations of posterior cranial fossa were recorded as per the international standards. Congenital malformations were assessed with USG and followed with MRI wherever applicable.

EQUIPMENT : USG SAMSUNG HS 70 A , CT – Elite bright speed, MRI – GE Signa explorer 1.5T .

International standard imaging protocols for CT and MRI were followed in all the cases.

Results

We have detected 35 number of posterior cranial fossa malformations as follows :

Address for correspondence
Dr. B. Mallikarjunappa, Professor, Department of Radio-diagnosis, PESIMSR, Kuppam - 517425, Andhra Pradesh, India
Email: drmallikarjunappa@gmail.com

Received: 14.08.18
Accepted: 28.12.18

Posterior cranial fossa malformations/ lesions.

Sl No.	Name	No. of cases
1	Cerebellar hypoplasia	1
2	MCM	2
3	Blake's pouch Cyst	2
4	Occipital Encephalocele	1
5	DWM	1
6	ACM II and III	3
7	Arachnoid cyst	1
8	PICA infarct	5
9	PRES	3
10	Wallenburg Syndrome	1
11	Metastasis	1
12	Tuberculoma	1
13	Cerebellar hemorrhage	2
14	Fahr's disease	1
15	Medulloblastoma	1
16	Pilocytic Astrocytoma	1
17	Medulloblastoma	1
18	Vestibular schwannoma	2
19	Jugular foramen schwannoma	1
20	Epidermoid	1
21	Meningioma	2
22	Neurocysticercosis	1

Discussion

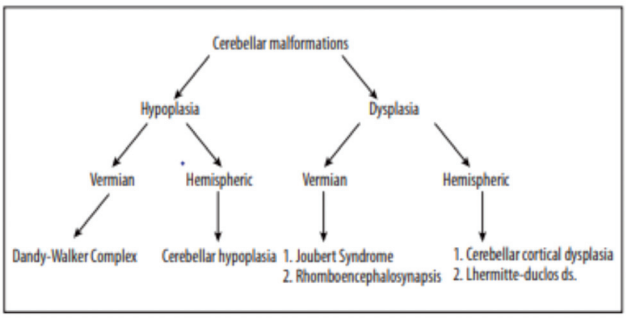

Schematic representation of cerebellar malformations

The most common congenital abnormalities of the posterior cranial fossa we encountered are

Megacisterna Magna (n=2)

Megacisterna magna and arachnoid cyst should be considered in the differential diagnosis of posterior cranial fossa cystic lesions. Mega cisterna magna (10 mm) does not cause any mass effect unlike arachnoid cyst, does not cause scalloping of calvarium nor will have communication with fourth ventricle nor displace torcula hereophili.

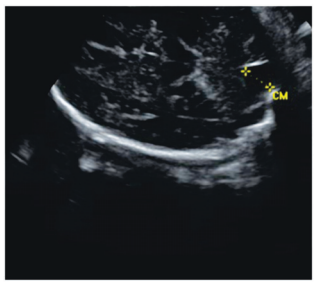

Fig.1: Antenatal USG image showing cisterna magna >10 mm in transcerebellar view and vermis appears normal.

Blake Pouch Cyst

Blake Pouch Cyst (n=2) is considered as a differential diagnosis for posterior cranial fossa cysts as it is characterised by ballooning of superior medullary velum into the cisterna magna, however it shows normal vermis and cisterna.

Dandy Walker Malformation

Dandy Walker Malformation (n=1) is due to teratogen exposure resulting in developmental arrest of hind brain formation. It consists of cerebelllar vermian hypoplasia, cystic dilatation of fourth ventricle, large posterior cranial fossa, high riding torcula heterophili with obstructive hydrocephalus. USG findings were confirmed by MRI.

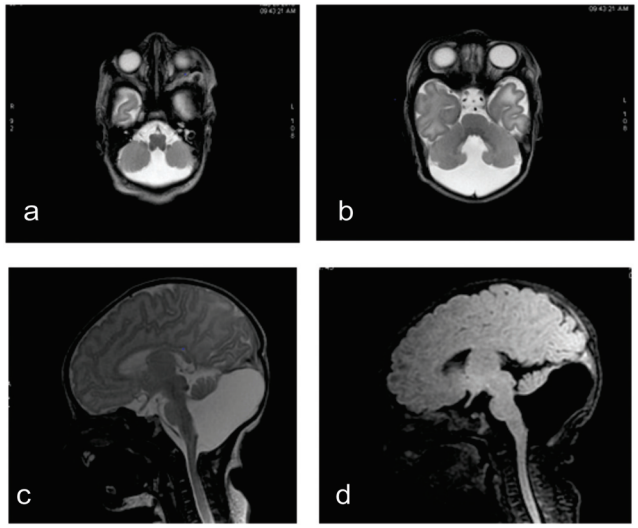

Dandy Walker Malformation

Fig.2 (a and b): Axial T2W, (c) Sag T2W and (d) Sag T1 FLAIR MRI images showing cystic dilatation of fourth ventricle, large posterior cranial fossa and cerebelllar vermian hypoplasia.

(e) Corresponding USG image shows large posterior cranial fossa cyst communicating with the fourth ventricle with cerebelllar vermian hypoplasia.

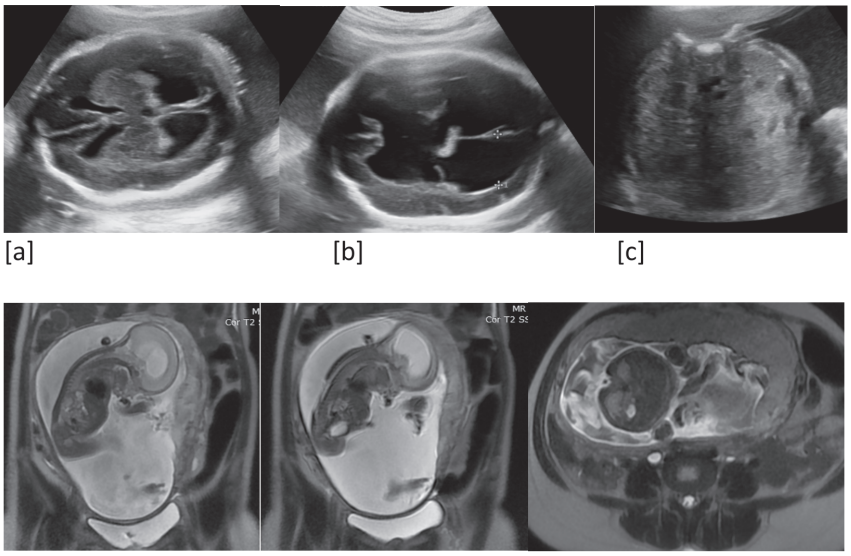

Chairi II Malformation

Fig. 3: Antenatal scan of 25 weeks gestation showing (a) lemon sign with mild scalloping of the frontal bone. (b) Gross hydrocephalus. (c) Splaying of dorsal ossification centers with everted lamina and spina bifida at lower dorsal and upper lumber vertebra with overlying skin defect. (d & e) MRI T2 image showing tonsillar herniation into the cervical canal with shallow posterior cranial fossa. (f) MRI T2 axial image showing spina bifida aperta.

Chairi II Malformation

Chairi II Malformation (n=2) is a complex neural tube defect involving the spinal cord and the hind brain. ACM-II is characterised by following radiological and pathological findings, herniation of inferior vermis, medulla, pons and 4th ventricle into cervical spinal canal. Osseous abnormalities like small posterior fossa, lacunar skull, petrous clivus scalloping and enlargement of foramen magna. Dural anomalies like hypoplasia and fenestration of the falx, low insertion of tentorium, tentorial hypoplasia with wide insucira; Quadregeminal plate stretched inferior and posteriorly, resulting in typical beak shape. Cerebellum can wrap itself around the brain stem. Buckling of medulla posterior to cervical spinal cord and small posterior cranial fossa and also seen. Ultrasoundand Mri features are Lemon sign, Ventriculomegaly, Banana sign: cerebellar tonsillar herniation into foramen magnum and effacement of cisterna magna.]

ACM III (n=1) is a rare entity characterized by chairi II malformation with occipital encephalocele.

Vascular Pathologies

As posterior cranial fossa comprises of cerebellum, mid brain, pons and medulla oblongata, the vascular pathology in terms of infarct and hemorrhage are quite rare compared to supra tentorial vascular pathology. The vascular territory comprises of PICA, superior cerebellar artery and posterior cerebral artery.

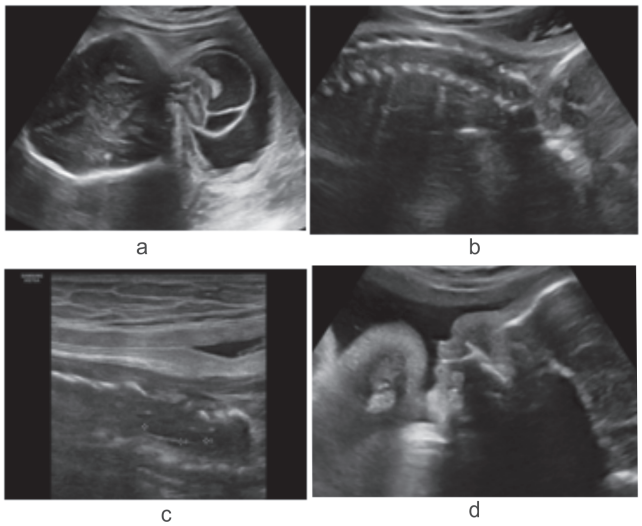

ACM III

Fig. 4: Antenatal scan of 32 weeks showing (a(Lemon sign, occipital encephalomyelocele. (b & c) Showing spina bifida with syrinx at upper cervical vertebra suggestive of ACM type III. (d)USG image Showing Absent nasal bone.

Posterior Reversible Encephalopathy Syndrome (PRES): (n=3)

Posterior reversible encephalopathy syndrome (PRES) is a neuorotoxic state secondary to failure of autoregulation of posterior circulation due to hypertension, hypoperfusion, vasogenic edema.

Commonest causes are postpartum eclampsia, acute glomerulonephritis, drug toxicity, sepsis and haemolytic uremic syndrome.

The classic imaging findings are of vasogenic oedema in the subcortical white matter of the parietal and occipital lobes.

PICA territory infarct: (n=5)

Cerebellar infarcts are more common than hemorrrhage constitute only 1-2 % of stroke.

Superior cerebellar artery (SCA), posterior inferior cerebellar artery (PICA) and anterior inferior cerebellar artery(AICA) are involved. The mortality rate of infarcts in this region is quite high with figures of about 20-50% and early correct diagnosis is crucial to prevent potentially fatal complications like brainstem compression and obstructive hydrocephalus.

On MR, wedge shaped area of altered signal intensity (hypointense on T1 and hyperintense on T2 & FLAIR) is seen involving both grey and white matter of a particular arterial distribution along with the evidence of mass effect and diffusion restriction.

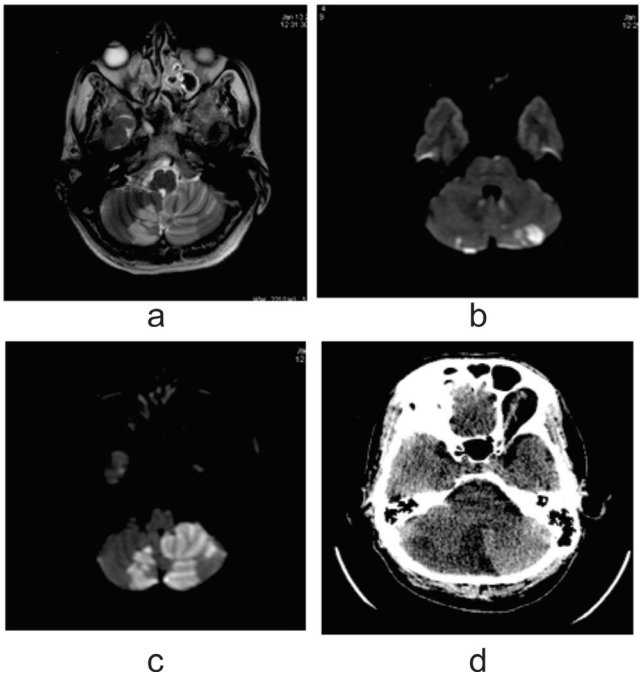

PICA territory infarct

Fig 5: (a) Axial T2 WI showing hyperintensities in inferior cerebellum, (b and c) on DWI, these areas are showing diffusion restriction. (d) Axial non contrast CT showing hypodense area in right inferior cerebellum.

Cerebellar hemorrhage (n=2)

Cerebellar hemorrhages comprise only 10% of all brain hemorrhages. The most common etiological factor is uncontrolled hypertension, other causes being vascular malformations and neoplastic bleed. MR signal intensity characteristics depend on the stage of bleed.

Wallenburg syndrome (n=1)

Wallenberg syndrome is a clinical entity charactarised by ipsilateral diplopia, nystagmus, horner syndrome, hiccups, dysarthria, horseness of voice, dysphagia, pain and temperature sensation due to acute ischemic infarct of lateral medulla oblongata secondary to verterbral artery, PICA and its branches.

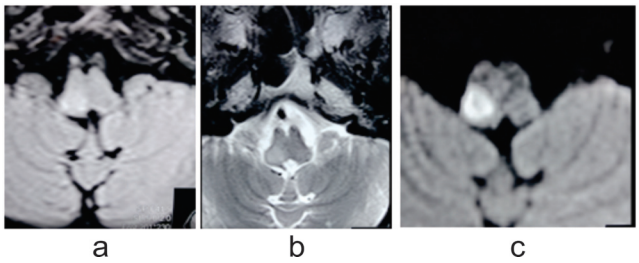

Wallenburg syndrome

Fig. 6: (a) Axial FLAIR, (b)T2W are showing hyperintensities in medulla oblongata. (c) DWI image is showing diffusion restriction in the same area.

Infective conditions

Tuberculoma (n=1)

Tuberculoma can occur in isolation or with tuberculous meningitis and is more common in endemic areas. Multiple conglomerated varying sized ring enhancing lesions will be present with or without calcifications (CT features).

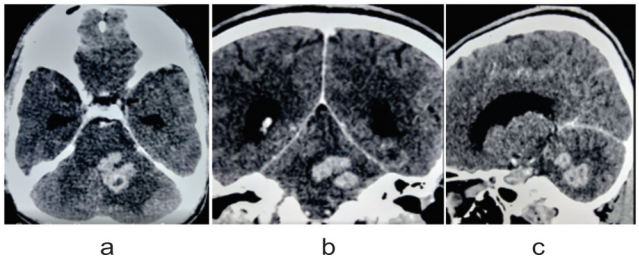

Tuberculoma

Fig. 7: (a) Axial, (b) coronal and (c) sagittal contrast enhanced CT images showing conglomerate ring enhancing lesions in posterior fossa.

Intraventricular Neurocysticercosis (n=1)

Intraventricuclar neurocysticercosis is a rare entity. Presence of scolex inside the cyst confirms the diagnosis.

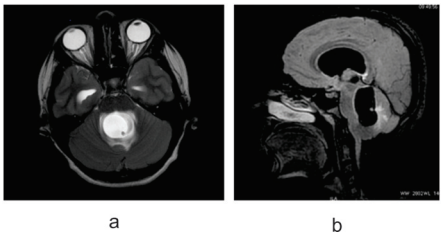

Intraventricular neurocysticercosis

Fig. 8: (a) Non contrast axial T2 and (b) Sagittal FLAIR images are showing cyst within the fourth ventricle with scolex inside.

Tuberculoma and neurocysticercosis shoud be differentiated as follows:

Conglomerated lesions are most commonly seen in tuberculoma.

Magnetisation transfer ratio - higher in neurocysticercosis where as low in case of tuberculoma.

MR spectroscopy in Neurocysticercosis shows multiple amino acid peaks and in tuberculomas shows lipid peak.

Fahr's Disease (n=1)

Fahr's Disease is an uncommon familial neurodegenerative disorder which is characterized by abnormal cell loss and calcium deposition in basal ganglia (mainly globus pallidus), internal capsule, dentate nucleus, thalamus, cerebellar and cerebral white matter. The etiology is still not clear.

We report a case of incidental staiato - dento - pallido calcification. As the patient presented in this age , so it is likely secondary.

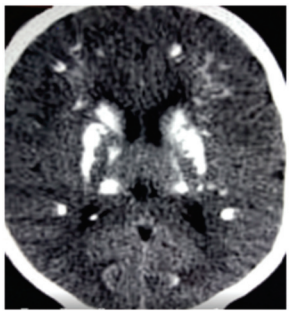

Fahr's Disease

Fig 9 : Axial non contrast CT image showing calcium deposition in bilateral basal ganglia, thalami and in dentate nuclei [Image not shown].

Posterior Fossa Tumours

The most commonest posterior cranial fossa tumours involving cerebellum are juvenile pilocytic astrocytoma , medulloblastoma, ependydoma.Commonest extra axial posterior cranial fossa tumours are vestibular schwannoma, epidermoid, meningioma and arachnoid cyst.

Juvenile Pilocytic Astrocytoma (n=1)

These are WHO grade 1 tumors which tend to occur in first two decades of life. They most commonly arise in the cerebellum (with most tumors involving both the vermis and the hemisphere) and comprise 85% of cerebellar astrocytomas. On imaging, most tumors demonstrate large cystic lesion with an intensely enhancing mural nodule. The wall of the cyst may or may not show enhancement. Less commonly, they are seen as mixed solid, cystic tumors and completely solid tumors are extremely rare. Solid component is hypointense on T1 and hyperintense on T2 weighted sequences. Surrounding vasogenic edema is extremely uncommon. Neurofibromatosis-1 is commonly associated with this tumor. The prognosis is good and complete surgical resection is usually curative. Recurrence and disseminated disease are extremely uncommon.

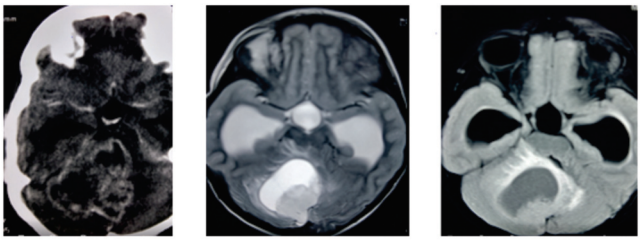

a b c

Juvenile pilocytic astrocytoma

Fig. 10 : (a) Axial contrast enhanced CT image showing cystic lesion in the posterior fossa with enhancing solid component (b) Axial T2 W and (c) FLAIR MRI images showing cystic lesion with mural nodule.

Medulloblastoma (n=1)

They are WHO grade 4, extremely cellular, small round blue cell tumors and are also known as CNS Primitive neuroectodermal tumors. The median age of occurrence is 9 years and most of them occur in males with a M:F ratio of 2–4:1. Their most common location is cerebellum with three-fourths arising in the vermis. Obstructive hydrocephalus is common due to protrusion into the fourth ventricle from its roof. They may also involve brainstem. As they are densely cellular tumors, these are hyperdense on CT, isointense on T1 and T2 weighted sequences with restricted diffusion on diffusion weighted sequence. Cyst formation and necrosis is common and is seen in 40–50% and calcification is seen in 10–20% of cases. It is important to acquire contrast enhanced MR of the entire neuraxis to screen for drop metastasis and leptomeningeal spread, as CSF seeding is common in these patients.

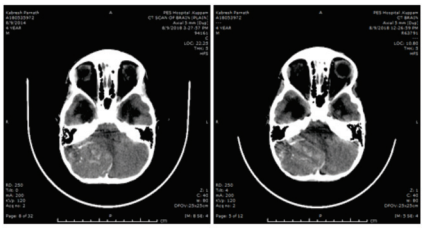

a b

Medulloblastoma

Fig. 11: (a) Axial non contrast CT image showing iso to hyperdense mass lesion with peripheral and internal calcifications in posterior fossa on right side in 4 years child. (b) Axial contrast CT image showing enhancement of the mass lesion in posterior fossa.HPE confirmed the diagnosis of medulloblastoma.

Extraaxial tumours of posterior fossa

Vestibular Schwannoma (n=2)

These are relatively common tumours that arise from the vestibulo- cochlear nerve and represent 80 % of cerebello pontine angle masses. Bilateral acoustic schwannomas are suggestive of neurofibromatosis type 2 [NF2].

These tumours classically present on imaging as a nodular mass with an intra canalicular component that often results in widening of porus acusticus .They usually show intense enhancement and when larger, cystic degeneration can be present. Hemorrhagic areas may also be seen, but calcifications typically not present.

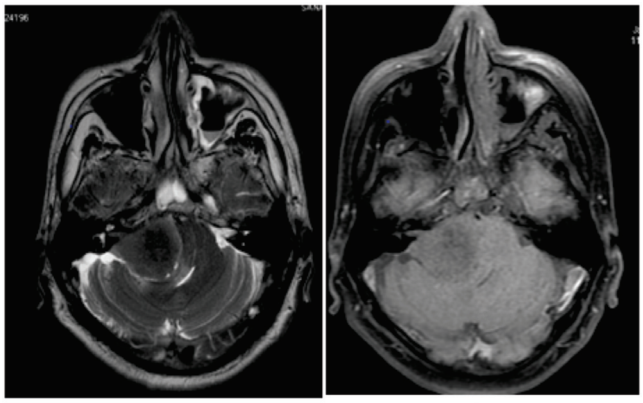

a b

Vestibular schwannoma

Fig. 12: (a) T2 Axial and (b) FLAIR MR images showing cerebellopontine angle mass with "***Ice Cream Cone***" appearance.

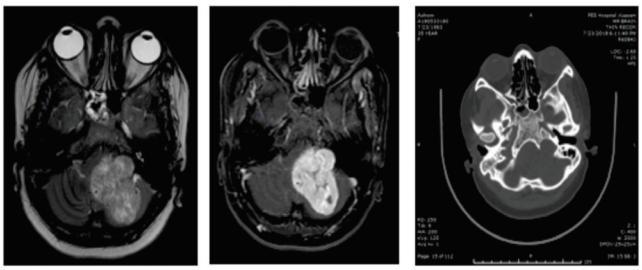

a b c

Jugular foramen schwannoma (n=1)

Fig. 13: (a) Axial T2, (b) T1 post contrast MR images showing intensely enhancing jugular foramen schwannoma. (c) CT axial image in bone window showing smooth widening of left jugular foramina.

Epidermoid (n=1)

These are are relatively common congenital lesions which account for about 1% of all intracranial tumours. Intracranial epidermoid cysts appear as lobulated lesions that fill and expand CSF spaces and exert a gradual mass effect, insinuating between structures and encasing adjacent nerves and vessels. Diffusion restriction helpful in differentiating epidermoid cyst from arachnoid cyst. Epidermoid cyst shows diffusion where as diffusion restriction is abscent in arachnoid cyst.

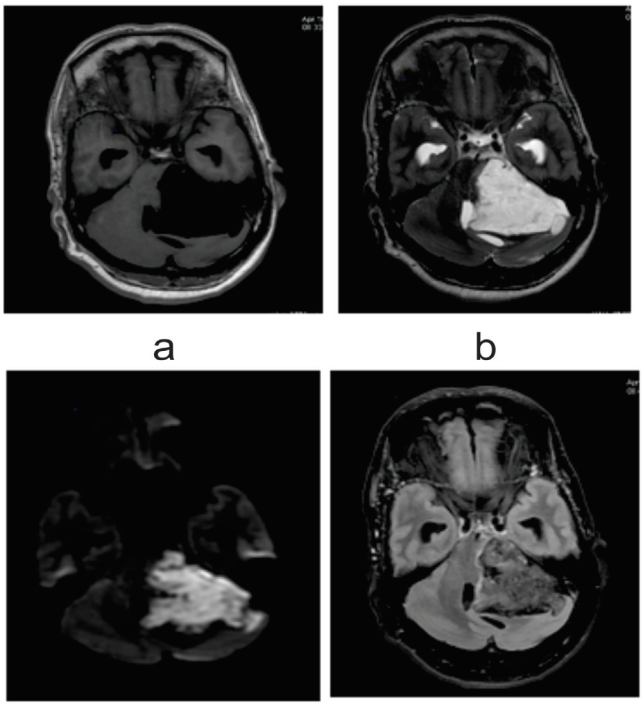

a b

c d

Epidermoid cyst

Fig. 14: (a) Axial T1 W MR image showing hypointense lesion in the posterior fossa (b) Axial T2 W MR image showing hyperintense lesion in the posterior fossa (c) DWI is showing diffusion restriction in the same area (d) Axial FLAIR image is sowing heterogenous signal FLAIR in the same area.

Meningioma (n=2)

Meningiomas represent approximately 15% of all symptomatic and about 33% of all incidental (asymptomatic) intracranial neoplasms.

The most common locations include the cerebral convexity, parasagittal, and sphenoid wing regions. Computed tomography (CT) demon strates typical diagnostic features, sharply circumscribed unilobular extra-axial mass with a broad-based dural attachment, On NECT the mass appears as an area of homogeneous hyperattenuation and on CECT the mass homogeneously enhances. On magnetic resonance (MR) images, the typical features of meningiomas include a unilobar mass with sharply circumscribed extra-axial mass. On MR images obtained without contrast material enhancement, meningiomas are characteristically hypointense to isointense with T1-weighted pulse sequences and isointense to hyperintense with T2-weighted pulse sequences. On MR images obtained with gadolonium, the mass homogeneously enhances. Meningiomas usually demonstrate a prominent and persistent blush on

angiograms, and the most frequent calvanial change is hyperostosis of the adjacent skull, which may be seen on plain radiographs, as well as on CT and MR.

Coronal CT images showing hyperdense cerebello pontine angle mass lesion.

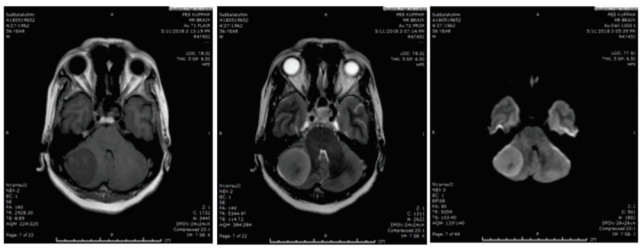

a b c

Meningioma

Fig. 15 : (a & b) Axial T1 and T2 images showing extra axial lesion which is appearing as T1 predominantly hypo, T2 predominantly hyperintense and the lesion is showing diffusion restriction on DWI (c) Histopathology confirmed the diagnosis of meningioma.

Arachnoid Cyst (n=1)

These are relatively common benign and asymptomatic lesions occurring in association with the central nervous system. On imaging, they are characterised as well circumscribed cysts, with an imperceptible wall, displacing adjacent structures, and following the CSF pattern (hypodense on CT and hyperintense on T2 with FLAIR suppression on MRI). They can also have a remodelling effect on the adjacent bone.

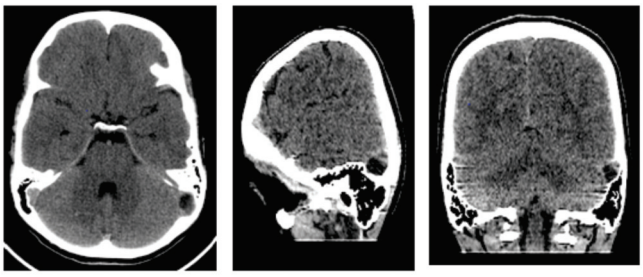

a b c

Arachnoid cyst

Fig. 16 : (a, b and c) Axial, sagittal and coronal non contrast CT images showing well circumscribed extra axial CSF dense lesion in the posterior fossa causing mild scalloping of inner table of skull.

Metastasis (n=1)

Cerebellar metastasis is rare compared to cerebrum. The most common primary tumors to have cerebellar metastasis are CA lung, CA breast, melanoma and rarely GI malignancies. MRI is the imaging modality of choice as MRS/Gradient can differentiate Cystic/Hemorrhagic and calcified metastasis.

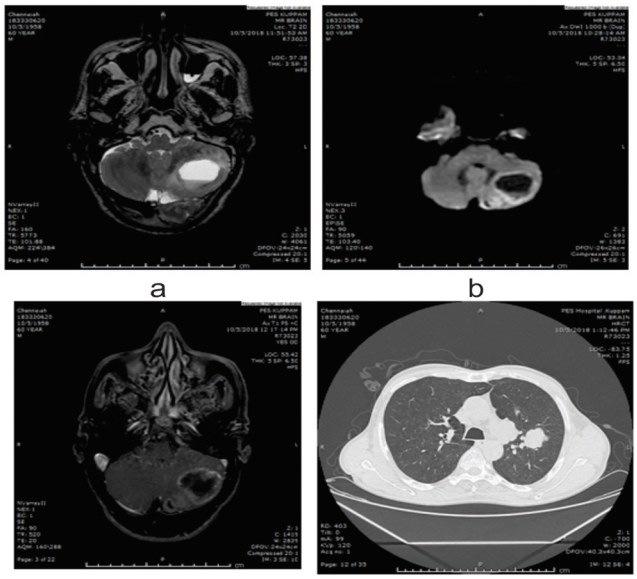

a b

c d

Metastasis

Fig. 17 : (a) Axial T2 WI showing well defined hyperintense lesion in the left cerebellar hemisphere. (b) DWI showing no diffusion restriction in the centre of the lesion. (c) Post contrast T1W axial image showing peripheral rim enhancement of the lesion with central non enhancing area. (d) Axial CT in lung window showing nodular lesion with spiculations in the left lung.

Conclusion

The complex anatomy of the posterior cranial fossa can be detected by high resolution USG ,CT and MRI.

Masses in the posterior fossa may be divided into extra-axial and intra-axial lesions. Because of its multiplanar capabilities, improved soft -tissue resolution and contrast, and the absence of scanning artifacts related to the osseous skull base, which are frequently present on CT, MRI is the imaging modality of choice in evaluating lesions arising in the posterior fossa. It is the best means of critically localizing lesions and determining the extent of disease.

DWI and GRE images are used to differentiate the vascular pathologies.

MDCT and MRI are helpful in characterising cystic , solid or mixed intra and extra axial lesions in the posterior cranial fossa specially in the case of epidermoid cyst and arachnoid cyst.Role of fetal MRI as an approach to practise in neuro radiology is paramount importance and we share our exerience with the commonest posterior cranial fossa lesions with classical imaging features.

We are greatful and thankful to Dr. Roopa Suresh, Dr. Suresh Krishnamoorthy, AMD & MD of PESIMSR, Dr. Krishna Rao, Principal and Dr. Venugopal, Medical Superintendent for their continued support in academics.

Conflict of interest:	All authors declare no COI
Ethics:	There is no ethical violation as it is based on voluntary anonymous interviews
Funding:	No external funding
Guarantor:	Dr. B. Mallikarjunappa will act as guarantor of this article on behalf of all co-authors.

References

1. Yuh EL, Barkovich AJ, Gupta N. Imaging of ependymomas: MRI and CT. Childs Nerv Syst. 2009 Oct;25(10):1203-13.
2. Rockhill J, Mrugala M, Chamberlain MC. Intracranial meningiomas: an overview of diagnosis and treatment. Neurosurg Focus. 2007;23(4):E1.
3. Cotes C, Bonfante E, Lazor J, Jadhav S, Caldas M, Swischuk L, Riascos R. Congenital basis of posterior fossa anomalies. Neuroradiol J. 2015 Jun;28(3):238-53.
4. Bartynski WS, Boardman JF. Distinct imaging patterns and lesion distribution in posterior reversible encephalopathy syndrome. AJNR Am J Neuroradiol. 2007 Aug;28(7):1320-7.
5. Stevens CJ, Heran MK. The many faces of posterior reversible encephalopathy syndrome. Br J Radiol. 2012 Dec;85(1020):1566-75.
6. Poretti A, Meoded A, Huisman TA. Neuroimaging of pediatric posterior fossa tumors including review of the literature. J Magn Reson Imaging. 2012 Jan;35(1):32-47.
7. Plaza MJ, Borja MJ, Altman N, Saigal G. Conventional and advanced MRI features of pediatric intracranial tumors: posterior fossa and suprasellar tumors. AJR Am J Roentgenol. 2013 May;200(5):1115-24.
8. Patel S, Barkovich AJ. Analysis and classification of cerebellar malformations. AJNR Am J Neuroradiol. 2002 Aug;23(7):1074-87.
9. Chourmouzi D, Papadopoulou E, Konstantinidis M, Syrris V, Kouskouras K, Haritanti A, Karkavelas G, Drevelegas A. Manifestations of pilocytic astrocytoma: a pictorial review. Insights Imaging. 2014 Jun;5(3):387-402.
10. Koeller KK, Rushing EJ. From the archives of the AFIP: pilocytic astrocytoma: radiologic-pathologic correlation. Radiographics. 2004 Nov-Dec;24(6):1693-708.
11. Geerdink N, van der Vliet T, Rotteveel JJ, Feuth T, Roeleveld N, Mullaart RA. Essential features of Chiari II malformation in MR imaging: an interobserver reliability study—part 1. Childs Nerv Syst. 2012 Jul;28(7):977-85.