

Excision of Lingual thyroid - How I do it.

Maharajan Chandrasekaran

Endocrine Surgeon, McArthy Thyroid Clinic, Chennai

Key words: Suprahyoid approach, Lingual Thyroid, Chandrasekaran Operation.

World over 3 Surgical approaches are commonly used to excise Lingual thyroid. They are

- (1) Lateral pharyngotomy approach,
 - (2) anterior approach where the tongue is bisected and the mandible is split in the middle and
 - (3) endoscopic trans oral approach.
- All three procedures are not only time consuming and morbid but are also associated with profuse bleeding.

Suprahyoid Approach:

CHANDRASEKARAN OPERATION- FOR LINGUAL THYROID

I have designed a unique technique for excising Lingual thyroid through a different route - suprahyoid approach- in which the lingual thyroid is excised under direct vision. The entire procedure can be performed within 45 minutes with minimal blood loss (less than 30ml.) The results have been excellent in all cases and patients were started on liquid diet on the 6th post operative day. Above all, this procedure can be performed by a surgeon with ease and without complications and blood loss. Hence, I strongly recommend this Suprahyoid approach for excising the Lingual thyroid.

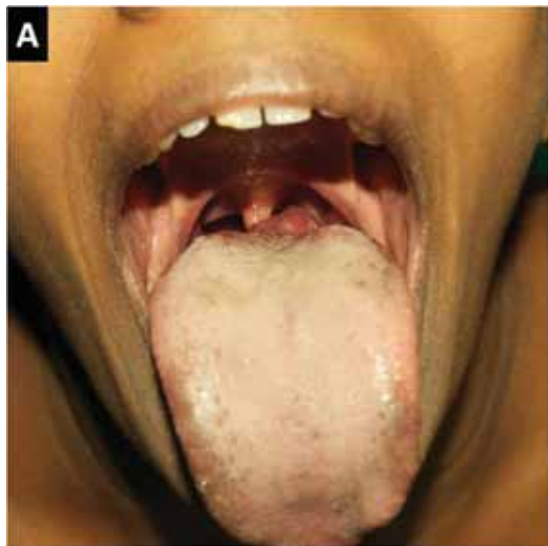

Fig. 1 - A. Lingual Thyroid

Correspondence: Dr. Maharajan Chandrasekaran, McArthy Thyroid Clinic, 14, Prakasam Street, T. Nagar, Chennai - 600017, India
e-mail : profmc@gmail.com

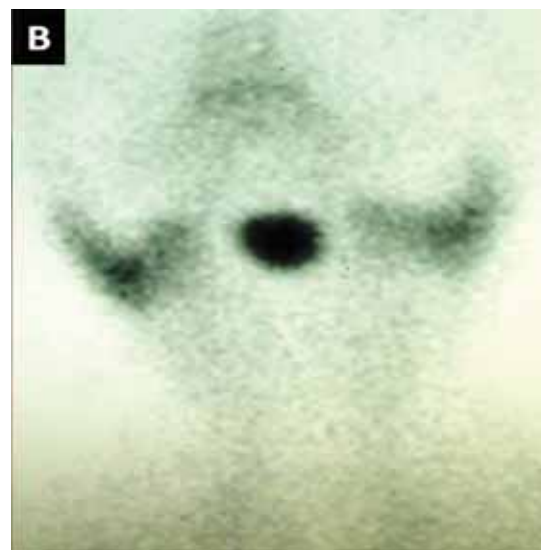


Fig. 1 - B: Tc-99m pertechnetate scan showing lingual Thyroid

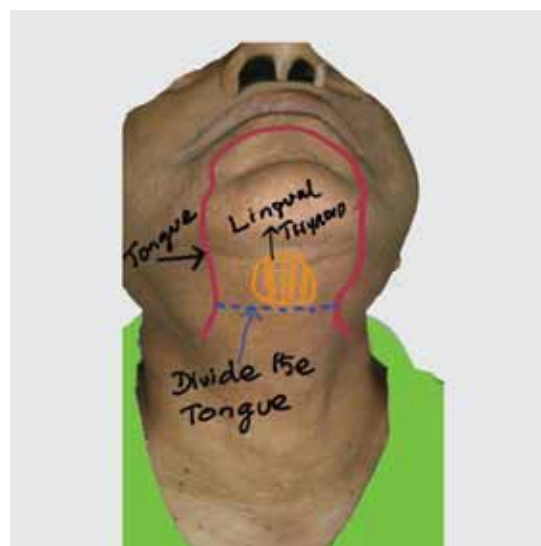


Image showing the site of incision on the tongue