

EFFICACY OF HERBAL MEDICATION FOR ENHANCING THE BREAST AND TEATS IN FEMALE WISTAR RATS

R. Karunanithi*, V. Pugalendi*, T.M.R. Panicker**, M. Paul Koraath***, K. Jagadeesan****

*Research Scholars, **Dean of faculties, ***Chief Physician,**** Founder and Director, K.J. Research Foundation
K.J. Hospital Research and Postgraduate Centre, 182, Poonamallee High Road, Chennai-60084, India

Abstract : An indigenous topical medication generally used by the practitioners of the traditional medicines containing plant material for breast tissue augmentation was used in this study. Phytoestrogens are a group of naturally occurring compounds such as; isoflavones, ligans, phytoosterols and saponins. The efficacy of this preparation was tested on wistar rats by regular topical application of the drug. Twenty five non pregnant female wistar rats weighing 150-200 gm were segregated in to four groups of five animals each, namely Group I- control, Group II – normal saline (0.9% NaCl solution) treatment, Group III – herbal preparation treatment, Group IV – a combination of treatment (left side – saline treatment and right side – herbal preparation treatment). The treatment of non – pregnant female rats with this herbal medication resulted in a significant increase in the volume of teats. The phytoestrogens present in the herbal medicine may have stimulated the breast and teats.
Key words: Breast development, phytoestrogens, Withania Somnifera, traditional medicine.

INTRODUCTION

The perceived inadequacy of the body image to popular ideas of the day can be a point of considerable distress in many individuals. The small size of mammae can be a source of distress for many young women. External application, internal medication, appliances, exercise and plastic surgery are resorted to alleviate the above mentioned problem.

Estrogen is the hormone that is necessary for mammogenesis or the development of the mammary gland. phytoestrogen are a group of substances found in plants that have estrogenic properties. Phytoestrogens, of female hormones level by causing an increase in estrogen effects, which is the body's primary source for breast enhancement. These stimulate the lengthening and branching out of these ducts and the development of the mammary tissue. They maximize blood flow and estrogen distribution throughout the breast tissue, encouraging development of breast tissue. It also helps to increase the fatty tissue and ligaments around the breast that provide support. Plants contain many types of phytoestrogens; additionally, they contain minerals and other constituents, which modify the phytoestrogens in the body thus making them safe to use².

Unlike drugs the herbs naturally nourish and tone the female system making them useful in a broad range of female conditions with no reported side effects.

Phytohormones actually appear to protect tissues from the cancer causing effects of xenoestrogens and other hormonal pollutants. Phytohormones have shown in clinical studies to lower the incidence of female related cancers i.e. breast, ovarian, endometrial, uterine etc. A pilot study in female wistar rats, which showed positive results¹ and hence an extended study was done. The aim was to study the effect of topical application of a herbal medication on breast and teats of female wistar rats.

Correspondence: Dr. K. Jagadeesan

Phone: 44-26411513, Fax: 044-26411886

e-mail: kjh@vsnl.net/kjh@rediffmail.com

MATERIALS & METHODS

An indigenous herbal preparation supplied by a practitioner of traditional medicine was used for topical application; the herbal medication consists of Withania somnifera (Linn), Piper longum (Linn.), Plumbago indica (Linn.) Acorus calamus (Linn).

Experimental Animals : Twenty five(25) non pregnant female wistar rats weighing 150-200 gm were segregated in to four groups of five animals each, namely; Group I - control, Group II – normal saline (0.9% NaCl solution) treatment, Group III – herbal preparation treatment, Group IV – a combination of treatment (left side – saline treatment and right side – herbal preparation treatment).(left side — saline treatment & right side – herbal preparation treatment). All the four groups were kept in separate cages after labeling them seriously with a dye. The hair on the chest & the abdomen was removed using Anne French hair removing cream. The animal had no access to male rats and were fed with pellets and adequate supply of water.

Application of the Drug : Group II animals were treated with a swab dipped in normal saline and stroked on the teats whereas, in group III animals test preparation was applied regularly using a swab twice a day at 9 A.M. and 9 P.M. These animals were maintained in similar conditions as mentioned throughout the period of the study.

Ethical Committee Clearance: This study was cleared by the K.J. Research foundation, KJ Hospital ethical committee and by the Committee for the purpose of control and supervision of experiments on animals (CPCSEA), Ministry of social justice and empowerment, Govt. of India.

Measurements of the teats size were taken at regular time intervals under a hand lens and using a millimeter scale. The bases of the teats were palpated for the presence or absence of breast button. The hind three pairs of teats were taken in to account for convenience during measurements. Hence, a total of thirty teats were measured from each group and the mean volumes of the teats were calculated by assuming the shape of the teat to be

an approximate cone. Volumes of the teats were calculated by using the formula of a cone i.e. $\frac{1}{3} \pi r^2 h$.

RESULTS & DISCUSSION

There was no statistically significant difference in the mean volume of the teats between the groups at the start of the study. By the end of the study period, all the groups except the control group showed statistically significant increase in the mean teats volume at $p=0.05$. There was no palpable breast button.

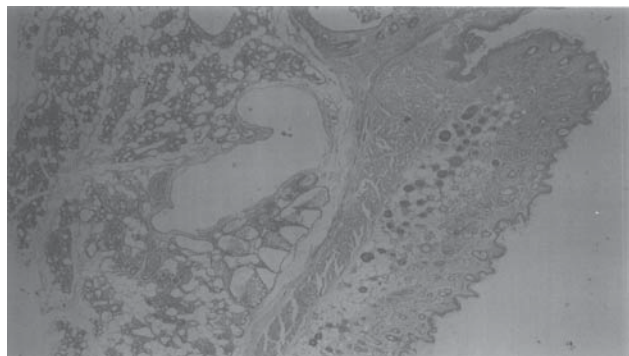


Fig. 1 : Showing overlying skin with mammae having numerous acini lined by cuboidal epithelium. Most of the alveoli contains eosinophilic material (H&E x 100)

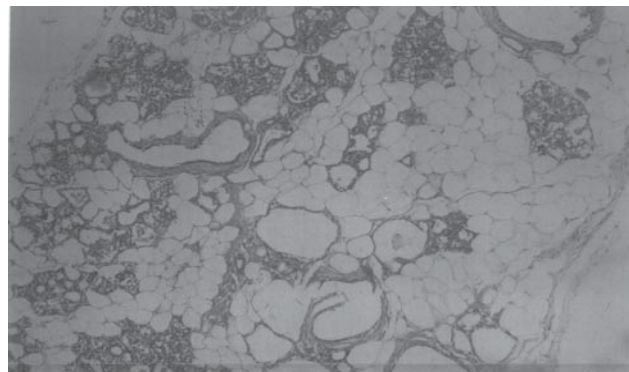


Fig. 2 : Showing the mammary tissue with fat cells and numerous ducts. Some of glandular acini show mild hyperplasia and contain eosinophilic secretion. (H&E x 400)

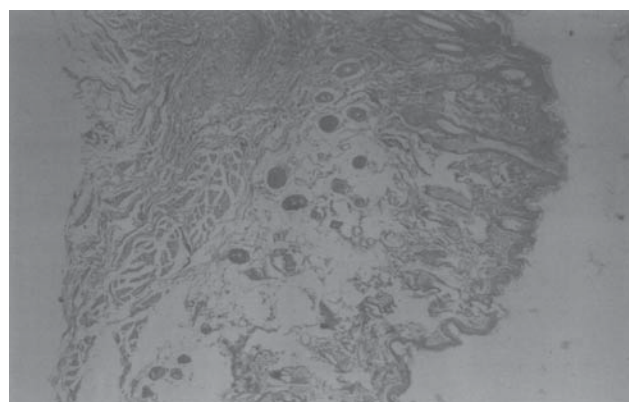


Fig. 3 : Skin-overlying mammary glands show acanthosis and mild hyperkeratosis (H&E x 400)

When compared to the control group (Group I) (mean 0.33 mm^3) the medication – receiving group (Group-III) (mean 0.87 mm^3) showed statistically significant increase in the mean volume of the teats (Fig.1 & Fig.2). Histological findings also supported this increase in teats volume to be due to the epithelium showing keratosis and fibroplasias with prominent retepeges. Prominent duct formation with mild hyperplastic cuboidal epithelium and numerous alveoli with hyperplastic changes (Fig.1) The lobules contained fat cells. Most of the alveoli contained eosinophilic contents. No neoplastic or malignant cells were observed. Similar histological findings were observed in left side teats of the Group IV animals receiving the medication treatment with a mean volume of the teats 0.66 mm^3 . This was statistically significant when compared to the control group.

Phytoestrogens present in the herbal preparation and stroking effect of the breast could have resulted in the increase in the volume of the teats in the medicine treated group of animals.

Group II animals receiving the saline treatment also showed statistically significant increase in the mean volume of the teats (mean 0.68 mm^3) when compared to the control group. Histological findings suggested that this increase in the volume of the teats to be due to hyperkeratosis with prominent retepeges (Fig.3) The effect of the saline together with the effect of stroking the animal may have caused this increase.

Similar histological findings were observed in right side teats of the Group IV animals receiving saline treatment with a mean volume of the teats 0.61 mm^3 . This was not statistically significant when compared to the control group. Histology did not detect ductal and alveolar changes in this group.

There was no significant difference between the teats volume between the left and right side of the teats of the Group IV both at the initial and at the end of the study period.

CONCLUSION

The treatment of non pregnant female rats with herbal medication resulted in a significant increase in the volume of teats. The phytoestrogens present in the herbal medicine may have stimulated the breast and teats by bringing hyperplastic changes, increase in the number of the alveoli of the mammary glands and also by the deposition of the fat cells in lobules resulting in increased volume of the breast tissue. Whereas, the saline application though showed significant increase, this was less than that of the medicine treatment. The histological findings did not indicate neoplastic or malignant changes in the herbal medicine treated animals and was thus safe to use.

REFERENCES

1. V. Pugalendhi, R.Karunanithi, TMR Panicker, et.al. A pilot study on the breast development in female wistar rats using an indigenous herbal preparation by topical application *Bombay hospital Journal* 2004, Vol.46, No.3.
2. Institute for environment and health, phytoestrogens in the human diet. MAFF, R & D Surveillance report 9 (Advanced health group) 197:291.
3. Brezinski A, Debi A. Phytoestrogens: the "natural selective estrogens receptor modulators" *Eur J Obstet Gynecol reprod boil* 1999;85:47-51.
4. Murkies AL, Wilcox G, Davis SR. Clinical Reviews 92 Phytoestrogens. *J. Clin Endocrinol metab* 1998;83:297-303.
5. Mc Michal Philips DE, et.al. Effects of soy-protein supplementation on epithelial proliferation in the histologically normal human breast. *Am J. Clin. Nutr* 1998;68:1431s-36s.