

AN EXPERIENCE OF 22 CASES OF HEPATIC AND PULMONARY HYDATIDOSIS IN 2 YEARS IN NEPAL

R.N.Das, Sushil Dawka

Department of Medicine, Manipal Teaching Hospital, Pokhara, Nepal

Abstract : 22 cases of hepato pulmonary hydatidosis were treated in a teaching hospital in an endemic zone of Nepal during 2 years period. There were 14 females and 8 males, age range of 14 to 68 years with a mean of 41 years were present for symptoms 5 months to 3 years and included chest discomfort breathlessness, haemoptysis, fever and dry cough. Preoperative computerized tomogram and post operative histopathology confirmed echinococcosis. Perioperative albendazole for 4 weeks was given to all 22 cases of pulmonary hydatidosis; Barrett's enucleation cystectomy wedge was done in 2 and segmental resection in 4 cases. Out of 8 cases with hepatic cysts hepatectomy, endocystectomy and pericystectomy, were performed in 3, 3 and 2 cases respectively; Scolicidals used during surgery were 20% saline and 5% providone – iodine.

INTRODUCTION

Pulmonary and hepatic hydatidosis is frequently seen in mid western Nepalan agripastoral valley, considered as an endemic zone. This ubiquitous disease is distributed world wide in endemic zones of agrarian countries of Asia. Mediterranean basin¹. Africa and South America especially among cattle raising farmers and shepherds². Man is an incidental host in dog sheep cycle of this cystode - Echinococcus granulosus, characterized by cystic lesions in various organs predominantly the liver the lungs.

MATERIAL AND METHODS

From March, 2001-Feb. 2003, we studied 22 patients, 14 females and 8 males; age range 14-68 years. We interviewed each patient assuring confidentiality in a questionnaire format including their detailed history of residence, occupation diet and cattle/dog/contact. They presented with prolonged dry cough, breathlessness, chest discomfort, duration of fever and haemoptysis was 5 months to 3 year Laboratory investigations included haemogram, liver and pulmonary function tests, sputum microscopy and chest radiograph. Preoperative thoracic computerized tomogram (CT), abdominal ultrasound; postoperative biopsy confirmed echinococcosis. All patients received albendazole for 4 weeks perioperatively and under went hepatic or pulmonary surgery.

RESULTS

There were 14 females and 8 males, youngest being a 14 year old girl and oldest was a 68 year old farmer (table 1). They patients presented with chest discomfort, breathlessness, haemoptysis (table 2); dry cough in the 16 cases and hepatomegaly in 8 cases. Duration ranged from 5 months to 3 years; 8 had hepatic lesions (Fig.1) confirmed as irregular round heterogenous hypoechoic mass on abdominal ultrasound. Chest skiagram showed 22 patients with solitary or multiple, unilateral or bilateral hypodense non homogenous 4-7 cm cystic lesions. (Fig. 2 and Fig.3) In our series, 14 patients had left sided and 8 patients had right sided pulmonary hydatidosis .

Correspondence: Dr. R.N. Das

e-mail : das_rabindranath@hotmail.com

Table 1: Age and sex distribution of hydatidosis

	male	female	total
age range	8	14	22
15-35 years	4	6	10
36-55 years	2	6	6
56-75 years	2	4	6

Table 2 : Clinical features of hydatidosis

Symptoms	male	female	total
Chest discomfort	2	4	6
Hemoptysis	2	4	6
Dry cough	3	6	10
Hepatomegaly	2	6	8
Breathlessness	4	4	8
Eosinophilia	2	2	4
Fever	2	4	6

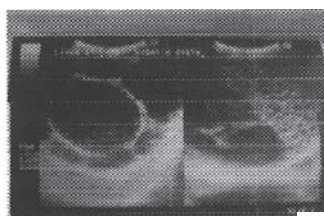


Fig.1. USG Rt Liver Lobe Cyst




Fig.2 Lt. Lung cyst (water lily sign)




Fig.3. huge Rt Lung Cystic lesions

The pulmonary cysts (22 cases) were dealt with Barrett's enucleation in 12 cases. Cystectomy in 4 cases wedge resection in 2 and segmental resection in 4 cases: **hepatic lesions** in 8 cases were health .hepatolobectomy in 3 cases endocystectomy in 3 cases and pericystectomy in 2 cases. Out of 22 patients, 8 had concurrent hepatic and pulmonary hydatidosis; 5 were operated up on through a thoraco – phreno laparotomic approach and 3 patients underwent a two stage operation. The therapeutic success was obtained by early diagnosis of echinococcosis, perioperative anthelmintic medication and adoption of timely surgical intervention (table 3). One stage echinococotomy from the liver

Table 3: Treatment modalities of hydatidosis

TREATMENT	MALE	FEMALE	TOTAL
Albendazole	8	14	22
Lung surgery	8	14	22
Liver surgery	2	6	8

and lung was the operation of choice in concurrent hepatic and right sided pulmonary hydatidosis. During surgery care was taken to avoid spillage of parasitic material. Abdominal packs soaked in povidone-iodine were carefully placed to isolate the operating field; this had the dual advantage of being dark in colour thus showing up spilled parasitic material by contrast, as well as being scolicidal. Before injecting the scolicidal agent, an equal or greater volume of cystic content was aspirated so as to avoid unplanned rupture, Scolicidals used were either 20% saline or 5% povidone-iodine intraoperatively.

Following this, the pericyst wall was firmly grasped and elevated to avoid spillage. The opening was then enlarged and th cyst contents were evacuated by pulling on the collapsed laminated membrane and meticulously removing all daughter cysts and jelly – like materials, Various methods were adopted to obliterate the residual large cavity. In 3 patients capitonnage (approximation of the pericyst walls) and in 2 omentoplasty (packing the cavity with vital omentum were required.

DISCUSSION

Adult *Echinococcus granulosus* (dog tape worm), inhabits proximal third of dog's small intestine and lays eggs which are excreted in faeces. Ingestion of these eggs by secondary host (cattle and sheep) or incidental host (man), leads to development of gut oncospheres which penetrate mesenteric vessels and migrate through blood stream to distant organs³, particularly liver (75%), lungs (20%), brain (2%) muscle bone eye, skin and other tissues (3%). The oncosphere develops in to a cyst (hydatid bladder) with two walls, an outer ectocyst and an inner germinal endocyst from which new larvae (protoscolices) develop in large numbers⁴. In Nepal, lack of adequate governmental food and health inspection policy, enormous quantity of illegal slaughtering outside abattoirs and widespread habit of abandoning sheep and goat carcasses in grazing areas may be contributory factors causing persistence of these metacestodosis in the environment.

The symptomatic hydatids enlarge over many years, occupying whole of right hepatic lobe or either hemithorax; erode and compress bronchi, blood vessels and mediastinum resulting in long abscess, pleural effusion, pneumothorax, atelectasis or

persistent haemoptysis, rupturing in to bronchus to discharge salty sputum and may even asphyxiate patient occasionally⁵. In our study, the female preponderance 14 females and 8 males and left sided pulmonary hydatidosis as opposed to more common right sided affection of the lungs remained unexplained. Non specific prolonged cough (60% of cases), with or without haemoptysis is the most common pulmonary symptom in endemic regions of hydatidosis along with other differential diagnosis like chronic obstructive airway disease and pulmonary tuberculosis. Multiple pulmonary cysts occur in 40%, bilateral in 20% and 10% also have liver cysts. In studies done by Hosch et al⁶, 36 to 40 % of hepatic cysts and 27 to 67% of pulmonary cysts ruptured or become secondarily infected at time of diagnosis.

Abdominal or hepatic hydatidosis are mostly silent as the cyst grows relentlessly to a huge size to rupture in to the biliary system to produce jaundice, hepatomegaly, choledocholithiasis or cholangitis like features besides portal hypertension owing to portal vein occlusion and occasionally rupture into peritoneal cavity; may lead to anaphylactic shock.

Plain chest skiagram can diagnose over 90% of pulmonary cysts as well defined thin walled uni-or-bi-lateral, solitary or multiple round or irregular, heterogeneous lesions. The laminated internal membrane of partially ruptured and collapsed cysts may be seen floating on fluid water (lily sign; radiologically)⁷. A plain abdominal x-ray reveals in about a third of cases of hepatic hydatid, images of almost full circumference of calcified cyst. Alternatively, computerized tomography or magnetic resonance imaging confirm hydatid diagnosis. The cheaper and non invasive ultrasonography and technetium 99 scintigraphy are of value in abdominal imaging.

Sptom microscopy may reveal protoscolices as hydatid sand Casoni's test is positive in 90% of cases but now –a-days obsolete. Serological tests like complement fixation, indirect haemoagglutinaion, enzyme linked immunosorbent assay (ELISA) may help. And recently developed, immunoblotting test detecting antibodies specific for 8 kD, a subunit of antigen B and in particular Ig G4 subclass expression, seems most promising serodiagnostic tool⁸. In *pulmonary disease*, simple enucleation, cystectomy, wedge or segmental resection, lobectomy or pneumonectomy may be justified after accurate localization of size, site and number of cysts. Cystectomy, with or without resection, may be done for *liver disease* and common bile duct should always be explored in these cases. Rupture on cyst enucleation is reported in up to half of recurrence and infection may ensue.

Several sterilizing techniques are used before enucleation by a small aspiration followed by injection of scolicidal absolute alcohol, 20% hypertonic saline, less absorbable and less toxic 1% aqueous or polyvinylpyrrolidone iodine, aqueous cetrimide (1/1000) or 0.5% silver nitrate solution. Low viscosity of iodine gives with 5% povidone iodine was satisfactory because it was cheap, easily available scolicidal as well as gave darkish brown colour when used intraoperatively. Experimentally in rabbit model intraoperatively intracystic injection of alcohol and albendazole¹⁰ solutions or cyclosporine¹¹ in vitro as scolicidal agents have been used to show high efficacy rate in killing the protoscolices but

yet go be applied in humans. It may have potential application as a new therapeutic agent in the treatment of human hydatid disease in near future.

An alternative to open operation is ultrasound guided puncture, aspiration, injection and reaspiration) treatment which is commonly practiced in places with limited facility.

Latest laser technique surgery, technically highly demanding remains the treatment of choice. It carries a mortality rare of 1 to 3% and a recurrence rate of more than 10% reported.

Perioperative mebendazole, praziquanfold bendazole for 28 days may prevent recurrence. Other benzimidazole such as fluoromebendazole and combendazole are undergoing clinical trails.

CONCLUSION

A huge unestimated combined livestock and human financial loss due to hydatin disease is occurring in Nepal. There is no prophylactic dog anthelmintic or sheep and goat recombinant vaccination in this country. The beaucrats and policy makers should be apprised of this important health problem in the region. Further practices for improving treatment especially surgical intervention and for epidemiological investigation are needed. With limited facility in Nepal, the high therapeutic success was obtained by early diagnosis of echinococcosis, perioperative anthelmintic medication and adoption of timely surgical intervention. One stage echinococotomy from the liver and lung was the operation of choice in concurrent hepatic and right sided pulmonary hydatidosis.

ACKNOWLEDGEMENT

The principal author Dr. R.N. Das is grateful to Prof.K.J. Shetty, FRCP (Edin) HOD Department of Medicine, and Dr. D.P. Sarawat, the Medical Superintendent of Manipal Teaching Hospital and Prof. J.S. Nagra, Dean and Director, MCOMS and MTH for their support in writing this article .

REFERENCES

1. *Castiglia P, Solinas G, Sotgiu G, Palmieri A, Maida A, Dettori M. Epidemiology of hydatidosis in the province of Sassari, Italy. Parasitologica. 2004 46(4) 371-3.*
2. *Yaghan RJ, Bani-Hani KE, Heis HA. The clinical and epidemiological features of hydatid disease in Northern Jordan. Saudi Med J. 2004 25(7)886-9.*
3. *Bortoletti G, Gabriele F, Conchedda M. Natural history of cystic echinococcosis in humans. Parasitologia 2004 46(4): 363-6.*
4. *Larrieu E.J, Frider B. Human cystic echinococcosis : contributions to the natural history of the disease. Ann Trop Med Parasitol 2001: 95(7): 679-87.*
5. *Gao YS, Zhu MB, Guo YZ, Dil MT, Ar-xen, Wang Y, Chu YM, Wen H, Liang D, Li SC, Li CY Clinical analysis on hepatic hydatid disease in Yili river valley. Zhongguo Ji Sheng Chong Xue Yu Ji Sheng Chong Bing Za Zhi. 2005 28; 23(1): 10-3.*
6. *Hosch W, Hecker E, Kauffman GW, Junghans T. Cystic pukmonary lesion in a patient with cough and eosinophilia Chest 2004 126(6): 1982-4.*
7. *Xu M, Kuerban H, Kong C, Ge X, Zhang L, Wang L, Dong Z, Yu L. Imaging diagnosis and classification of hepatic cystic echinococcosis . Zhonghua Yi Xue Za Zhi. 2002 10:82(3): 176-9.*
8. *Siracusano A, Buttari B, Delunardo F, Profumo E, Margutti P, Ortona E, Rigano R, Teggi A Critical points in the immunodiagnosis of cystic echinococcosis in humans. Parasitologia 2004; 46(4) 401-3.*
9. *Sayek I, Tirmaksiz MB, Dogan R. Cystic hydatid disease : Current rtrends in diagnosis and management. Surg Today 2004; 34(12) 987-96.*
10. *Yetim I, Erzurumlu K, Hokelek M, Baris S, Derivisoglu A, Polat C, Belet UI, Buyukkarabacak Y, Guvenli A. Results of alcohol and albendazole injections in hepatic hydatidosis: experimental study J. Gastroenterol Hepatol . 2005 20(9):1442-7.*
11. *Colebrook AL, Jenkins DJ, Jones MK, Tatarczuch L, Lightowers MW Effect of cyclosporine A on the survival and ultrastructure of Echinococcus granulosus protoscoleces in vitro. Parasitology. 2004 : 129 (Pt 4): 497-504.*

DRUG PROFILE

Voglibose:

It is disaccharidase inhibitor that is a potent inhibitor of intestinal glucosidase that delays the digestion and absorption of maltose and sucrose.

Mechanism of Action: Voglibose is an alpha-glucosidase inhibitor, which inhibits the activity of maltase and sucrase in the brush border of the small intestine. Unlike acarbose, Voglibose appears to have minimal if any inhibitory effect on alpha-amylase. Minimal inhibitory effects facilitate mobilization of endogenous glucagons-like peptide-I, an effect which could contribute to the lowering of fasting blood glucose levels to increase insulin sensitivity in nondiabetic hyperinsulinemic subjects.

Pharmacokinetics: Voglibose is poorly absorbed after oral administration; has to be given with food. Since the amount orally absorbed is insignificant no specific changes to the pharmacokinetics occur if given before or after meals. Most of the drug is excreted unchanged in the faeces and urine.

Drug Interactions. As voglibose is only very slightly systemically absorbed, it has a low potential for interactions with other drugs.

Clinical Effects: Oral voglibose 0.6 to 1.8 mg daily has improved postprandial hyperglycemia in non-insulin-dependent diabetic patients; improvement in fasting blood glucose, reduction in glycosylated hemoglobin. Hence it is the preferred drugs for the treatment of Postprandial Hyperglycemia Incidence of hypoglycemia is effective

in decreasing the VAT (visceral adipose tissue area) (subcutaneous adipose tissue area) ratio. The reduction in the lipid profile is more prominent on triglycerides as compared to the other agents.

Indications and Usage: Voglibose is used mainly for controlling the post prandial hyperglycemia seen in patients of Type 2 Diabetes Mellitus (NIDDM). It can be used as an adjunct to diet, sulfonylureas or insulin therapy in NIDDM. The drug can be considered in Type I Diabetes to reduce the incidence of nocturnal hypoglycemia; preferred in hyperinsulinemic non diabetic patients and Glycogen Storage Disease.

Contraindications: Hypersensitivity to the active substance or to any of the excipients.

Precautions: Voglibose should be use with case in (a) GI disorders (associated with diarrhoea), (b) in patients with liver disorders in view of potential hepatotoxicity, (c) dosage adjustment is required for patients with mild and moderate renal impairment, (d) Not recommended for use in pediatric population, (e) studies have been done in patients of age 65 or higher.

Adverse Effects: Endocrine/metabolic effects, hepatic effects, gastrointestinal effects, neurologic effects. More commonly, gastrointestinal tract findings include soft stools/diarrhea, flatulence, bloating, abdominal pain or discomfort, abdominal fullness, nausea attributed to the presence of unabsorbed intestinal carbohydrates. Rise in liver enzymes; 20% suffer from hepatitis with severe cholestasis. Dizziness occurs in 10 to 20% following oral administration specially in elderly.