

ROLE IN BREAST CANCER¹⁴

MRE has a role as a tool for detection of malignant disease and for lesion characterization. In a study done on six healthy women and six patients with known breast cancer, tumors had 2.3 to 6.8 times the stiffness of adjacent breast tissue. Further research is needed to evaluate the potential applications of MRE.

Technique: An electromechanical driver, controlled by trigger pulses generated by the MR imaging sequence, generates shear waves with displacement amplitudes of typically less than 500 μm at the surface. A phase-contrast MR imaging sequence incorporates oscillating motion-sensitizing field gradients that are applied synchronously with the mechanical shear waves that traverse the imaged object. Cyclic motion of the material that is synchronized with the motion-sensitizing gradients causes a measurable phase shift in the received MR signal (Fig 9).

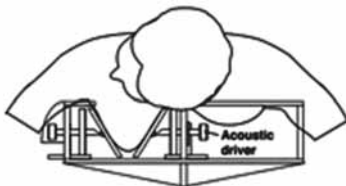


Fig 9a: Electromechanical drivers, integrated into radiofrequency coil unit

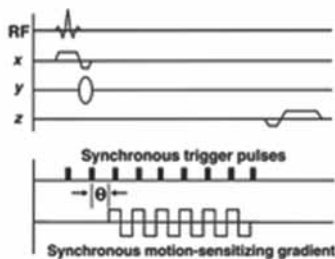


Fig 9b: Special gradient-echo phase-contrast MR imaging sequence: Trigger pulses from sequencing computer of imager are used to control acoustic driver, ensuring synchronization of applied acoustic waves with motion-encoding gradients.

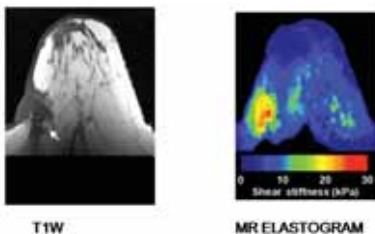


Fig 9c: Invasive ductal breast carcinoma in lateral breast

ROLE IN PORTAL HYPERTENSION¹⁵

MR elastography of spleen is feasible and shows promise as a quantitative method for predicting the presence of esophageal varices in patients with advanced hepatic fibrosis. Mean spleen stiffness was significantly lower in volunteers (mean, 3.6 kPa \pm 0.3) than it was in patients with liver fibrosis

(mean, 5.6 kPa \pm 5.0, range, 2.7–19.2 kPa; $p < .001$). In the setting of cirrhosis, the presence of esophageal varices was observed in 100% of patients with mean spleen stiffness values \geq 10.5 kPa.

CARDIAC MRE¹⁶

Preliminary studies have shown externally induced shear waves provide information reflecting intraventricular pressure changes which, if substantiated in further experiments, has potential to make cardiac MRE a unique noninvasive imaging modality for measuring pressure-volume function of the heart.

CONCLUSION

- ELASTOGRAPHY is a promising technique to non-invasively distinguish between benign and malignant lesions
- sonoelastography has an established role in thyroid, breast and prostate lesions
- MR ELASTOGRAPHY has shown promise for lesion characterization but needs further evaluation.

REFERENCES

1. Itoh A, Ueno E, Tohno E, Kamma H, Takahashi H, Shiina T et al. Breast Disease: Clinical Application of US Elastography for Diagnosis. *Radiol.* 2006; 239:341-350.
2. Dighe M, Bae U, Richardson ML, Dubinsky TH, Minoshima S, Kim Y. Differential Diagnosis of Thyroid Nodules with US Elastography Using Carotid Artery Pulsation. *Radiol.* 2008; 248:662-669.
3. Miyagawa T, Tsutsumi M, Matsumura T, Kawazoe N, Ishikawa S, Shimokama T et al. Real-time Elastography for the Diagnosis of Prostate Cancer: Evaluation of Elastographic Moving Images. *Jpn. J. Clin. Oncol.* 2009; 39: 394-398.
4. Alam F, Naito K, Horiguchi J, Fukuda H, Tachikake T, Ito K. Accuracy of Sonographic Elastography in the Differential Diagnosis of Enlarged Cervical Lymph Nodes: Comparison with Conventional B-Mode Sonography. *Am. J. Roentgenol.* 2008; 191: 604-610.
5. Giovannini M, Thomas B, Erwan B, Christian P, Fabrice C, Benjamin E, Genevieve M, Paolo A, Pierre D, Robert Y, et al. Endoscopic ultrasound elastography for evaluation of lymph nodes and pancreatic masses: a multicenter study. *World J Gastroenterol.* 2009;15:1587-1593.
6. Gheonea DI, Săftoiu A, Ciurea T, Gorunescu F, Iordache S, Popescu GL et al. Real-time sonoelastography in the diagnosis of diffuse liver diseases. *World J Gastroenterol.* 2010 April 14; 16(14): 1720-1726.
7. De Zordo T, Lill SR, Fink C, Feuchtnr GM, Jaschke W, Bellmann-Weiler R, Klausner AS. Real-time sonoelastography of lateral epicondylitis: comparison of findings between patients and healthy volunteers. *AJR.* 2009 Jul;193(1):180-5.
8. De Zordo T, Fink C, Feuchtnr GM, Smekal V, Reindl M, Klausner AS. Real-time sonoelastography findings in healthy Achilles tendons. *AJR.* 2009 Aug;193(2):W134-8.
9. Gaspari R, Blehar D, Mendoza M, Montoya A, Moon C, Polan D. Use of ultrasound elastography for skin and subcutaneous abscesses. *J Ultrasound Med.* 2009 Jul;28(7):855-60.
10. de Korte CL, van Hees N, Lopata RG, Weijers G, Katsaros C, Thijssen JM. Quantitative assessment of oral orbicular muscle deformation after cleft lip reconstruction: an ultrasound elastography study. *IEEE Trans Med Imaging.* 2009 Aug;28(8):1217-22.
11. Schaar JA, de Korte CL, Mastik F, Strijder C, Pasterkamp G. Characterizing vulnerable plaque features with intravascular elastography. *Circulation.* 2003;108:2636-2641
12. Huwart L, van Beers BE. MR elastography. *Gastroentérologie Clinique et Biologique.* 2008 Sept;32(6S1):68-72
13. Venkatesh SK, Yin M, Glockner JF, Takahashi N, Araoz PA, Talwalkar JA, Ehman RL. MR elastography of liver tumors: preliminary results. *AJR.* 2008 Jun;190(6):1534-40.
14. McKnight AL, Kugel JL, Rossman PJ, Manduca A, Hartmann LC, Ehman RL. MR elastography of breast cancer: preliminary results. *AJR.* 2002 Jun;178(6):1411-7.
15. Talwalkar JA, Yin M, Venkatesh S, Rossman PJ, Grimm RC, Manduca A, et al. Feasibility of in vivo MR elastographic splenic stiffness measurements in the assessment of portal hypertension. *AJR* 2009 Jul;193(1):122-7.
16. Elgeti T, Laule M, Kaufels N, Schnorr J, Hamm B, Samani A et al. Cardiac MR Elastography: Comparison with left ventricular pressure measurement. *J Cardiovasc Magn Reson.* 2009; 11(1): 44.

Next Issue Highlights

- **Editorial:** "Association of Hepatitis B & C with HIV / AIDS: Management Issues
- **Update:** Anaesthetic Considerations in Paediatric Patients
- **Symposium:** Metabolic & Bariatric Surgery: An Update

Future Special Issues/ Symposia

Special Issues

- Constipation: Emerging Horizons-II
- Advances in Pediatric Surgery
- HIV/AIDS: Emerging Trends

Symposia

- Advances in Endocrine Surgery
- Pain Management: Current Trends
- Sleep Disorders: Current Perspective