

Primary Myxoid Solitary Fibrous Tumour of the Seminal Vesicle: A Case Report.

N. Gopakumar, Sebastian Varghese, Venkiteswara Babu, R. N. Ramesh

Department of Urology & Radiology, PRS Hospital, Trivandrum, Kerala, India

Abstract: Primary myxoid solitary fibrous tumour of the seminal vesicle is rare. It is benign and requires surgery only if they are symptomatic. We report a 58 old man presented with microscopic hematuria and mass palpable per rectum just above the prostate. Trus guided trucut biopsy revealed primary myxoid fibrous tumour of the seminal vesicle. Since asymptomatic he is being followed up.

INTRODUCTION

Benign tumours of the seminal vesicle that occur more commonly than malignant ones include fibromas, leiomyomas, cyst adenomas, Schwannomas and papillary adenomas. High resolution TRUS has become the mainstay of imaging for the diagnostic evaluation of seminal vesicle pathology. CT is used to evaluate the seminal vesicles. A tumours within the seminal vesicle has higher attenuation than the normal seminal vesicle. Solid seminal vesicle masses that are on benign on biopsy should be treated with seminal vesiculectomy only if they are symptomatic. We present a rare case of primary myxoid solitary fibrous tumour of the seminal vesicle in a 58 year old man.

CASE REPORT

A 58 year old man presented to us 6th September 2013 with history of mild lower urinary tract symptoms of 1 month duration. Rectal examination revealed a mass just above the prostate non tender, firm. Laboratory examination revealed microscopic hematuria. Total counts, renal function were normal. On Transrectal Ultrasonography revealed hypoechoic firm nodular lesion seen in the right seminal vesicle. Poor vascularity was noted. Trus guided trucut biopsy was taken. Histopathology specimen low power and high power field shows stellate shaped cells in a background of myxoid stroma (Fig). CT scan revealed well defined hyperdense lesion seen involving right seminal vesicle with mild enhancement on contrast surrounding fat lines was clear. No regional lymphadenopathy was detected (Fig). Since he is not having many symptoms he is being followed up.

DISCUSSION

Although focal myxoid change is a well recognized features of solitary fibrous tumour predominantly myxoid solitary fibrous tumour is exceedingly rare¹. Solitary fibrous tumour is not as site restricted as once believed². Seminal vesicle involvement presented with hematuria or groin pain³. Benign tumours of the seminal vesicle occur more commonly than malignant ones^{3,4}.

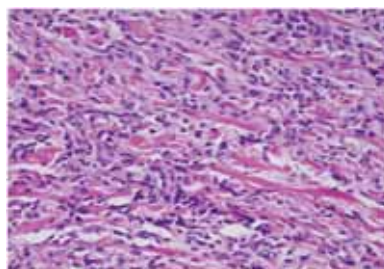
High resolution TRUS has become the mainstay of imaging in the evaluation of seminal vesicle pathology. CT is used to further characterize the seminal vesicle pathology. Tumour within seminal vesicle has a higher attenuation value than the normal seminal vesicle. MRI gives more anatomic details than CT and useful for staging^{6,7}.

The surgical attitude to myxoid solitary fibrous tumour of the seminal vesicle depends on the clinical symptoms and extent of the lesion^{2,5}.

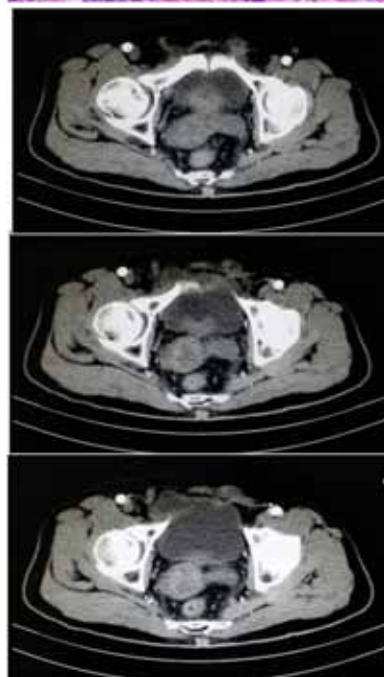
CONCLUSION

Solid seminal vesicle masses that are benign on biopsy and show no evidence of local spread can be followed up and require excision only if they are symptomatic which is a rare occurrence.

Correspondence: N. Gopakumar, Chief Urologist, Department of Urology & Radiology, PRS Hospital, Killippalam, Trivandrum 695002, India e-mail : drungkumar uro @ rediffmail.com



Histopathology



Primary myxoid solitary fibrous tumour of the seminal vesicle

REFERENCES

1. Weys, LICF, Sungm T, Chen Y T, Kosf, Eng HL, HunagHY. Primary myxoid solitary fibrous tumour (SFT) involving the seminal vesicle pathol Int 2006 Oct 55 (10) : 6242-4.
2. Morin G, Houlgatte .A, Camparro P, Sarrazu JL, Berlizot P, Houdelette P Solitary fibrous tumour of the seminal vesicle – Apropos of a case . Prog Urol 1998 Feb 8 (1) : 92-4.
3. Westra WH, Grenko RT, Epstein JSFT of the lower genital tract a report of five cases involving seminal vesicle, urinary bladder and prostate, Humpathol 2000 Jan, 31 (1) 63-8.
4. Funahashi Y, HattolxiR, Matsukawa Y, Yamamoto T, Mizutanik, Yoshino Y, Komastu T, Sassa N, Hagikura S., Gotoh. M Solitary FT of seminal vesicle, AktvilleUrol, 2010 : Sep 41 (5) 32 (-).
5. Wiessner D, Dittert DD, Maseck A, Wirth MP Large SFT of the seminal vesicle. Acurate conservative surgical treatment of the tumour . Urology 2003 Nov 62 (5) : 941.
6. Camp bell –Walsh , Urology . 10th Edition Vol 1 1014 -1015 ; 1021.
7. Kingeta BF, Hattery RR, Lieber MM . Seminal vesicle imaging, Radiographics 1989 , 9, 653, 676.