

Painful Hip in Young: MRI Evaluation of Avascular Necrosis.

Sumeet Bhargava¹, Amit Kumar Sahu²

Department of Radiology, ¹KB Healthcare Diagnostic Center, Greater Noida, Uttar Pradesh

²Max Superspeciality Hospital, Saket, New Delhi, India

Abstract

Objectives: Magnetic resonance imaging (MRI) evaluation of young patients presented with painful hip to the outpatient department. MRI findings of avascular necrosis (AVN) of hip was evaluated and staged for further management.

Methods: Patients between the ages of 15 to 50 years who presented to the outpatient department during last 1 year with painful hip were evaluated with a hip X-ray. Based on clinical suspicion of AVN of hip and X-ray findings, these patients were further referred for MRI examination. MRI of both hip joints were performed and evaluated for the cause of pain. Patients diagnosed with AVN of hip on MRI were given the radiological staging of the disease for further management.

Results: Total 36 patients with suspicion of AVN of hip (based on clinical examination or X-ray findings) were referred for MRI hip joints to evaluate for the cause of pain. There were 26 males and 10 females. Mean age group was 38 years. Twenty-one patients had abnormal X-rays of which 12 X-rays showed AVN. On MRI, 22(61%) patients had AVN of femoral head, 8 had other pathologies and 6 had no abnormal imaging findings. Fourteen of 22 (63.6%) had unilateral AVN and 8 (36.4%) had bilateral AVN. Thus there were total 30 femoral heads with AVN. According to Ficat and Arlet classification of AVN, Grade II (12 hips, 40%) was most common and according to Mitchell classification, Stage C (11 hips, 37%) was most common in our study. Two patients in bilateral group had grade II, stage B in one femoral head and grade II, and stage C in other femoral head. MRI detected AVN in early disease in majority of cases i.e., Grade I and Grade II combined 60% and Stage A and Stage B combined 56%. Among the 8 patients with other pathologies, 3 had hip joint Synovitis, 2 had bilateral sacroiliitis, 2 had early hip osteoarthritis and 1 had ilio-psoas bursitis. Ten of 22 (45%) patients with AVN had normal X-rays.

Conclusion: AVN of hip is not an uncommon finding in young patients with hip pain. X-rays can be normal in early stage of the disease. MRI is the modality of choice for early diagnosis of Hip AVN and for staging of the disease for appropriate management.

Keywords: Magnetic Resonance Imaging, Young Patients, Avascular Necrosis, Hip

Introduction

Avascular necrosis (AVN) or osteonecrosis of femoral head is usually a disease in young population and present with hip pain and gradual restriction of movement [1]. In early stage of the disease, the necrotic zone is visible in magnetic resonance imaging (MRI) with normal morphology of femoral head. In later stage, there is subchondral fracture and collapse with buckling of overlying articular cartilage

leading to end-stage secondary arthritis. MRI can diagnose the disease in early stage and can prevent the joint from arthroplasty which is the treatment in end-stage arthritis.

Material & Methods

The study included patients between 15 to 50 years of age who presented with hip pain to various outpatient departments and referred for MRI on clinical suspicion of having AVN hip. All patients were initially evaluated by X-ray of hip joints. It was a prospective study done in last 1 year duration. Total 36 patients were included in the study after taking written informed consent from all patients.

MRI examination of both hip joints was performed in 1.5 Tesla Siemens Avanto machine. Non-contrast MRI was done using routine T1, T2 and PDFS (proton density fat

Address for Correspondence

Dr. Amit Kumar Sahu, Consultant Radiologist, Max Superspeciality Hospital, Saket, New Delhi, India M : 7428304988
E-mail: drsahuamit@gmail.com

Received: June 2020

Accepted: October 2020

suppression) sequences in axial, coronal and sagittal planes. All the MRI studies were evaluated by two radiologists having 11 years and 9 years of experience to see for the cause of hip pain. Pathologies of individual hip joints were noted. Patients diagnosed to have AVN of femoral head on MRI were further evaluated and MRI staging of the disease was given based on Ficat and Arlet classification (Grade I – IV) and Mitchell classification (Stage A – D).

Results

Total 36 patients were included in our study. Twenty-six (72%) were males and 10 (28%) were females. Mean age of the patients was 38 years. Twenty-one (58%) patients had normal X-rays and 15 (42%) had abnormal X-rays. On MRI, 22 (61%) patients had AVN femoral head, 8 had pathologies other than AVN and 6 had normal MRI. Fourteen of 22 (63.6%) had unilateral AVN and 8 (36.4%) had bilateral AVN. Thus there were total 30 femoral heads with AVN. According to Ficat and Arlet classification of AVN, 6 femoral heads (20%) had Grade I disease, 12 (40%) had Grade II, 10 (33%) had Grade III and 2 (7%) had Grade IV disease. According to Mitchell classification, 7 femoral heads (23%) had Stage A disease, 10 (33%) had Stage B, 11 (37%) had Stage C and 2 (7%) had Stage D disease. Two patients in bilateral group had Grade II, Stage B in one hip and Grade II, Stage C in another hip. MRI detected AVN in early disease in majority of cases i.e., Grade I and Grade II combined 60% and Stage A and Stage B combined 56%. Among the 8 patients with other pathologies, 3 had hip joint Synovitis, 2 had bilateral sacroiliitis, 2 had early hip osteoarthritis and 1 had ilio-psoas bursitis. Among the 22 patients diagnosed with AVN on MRI, 22 (45%) had normal X-rays. [Table 1,2]

Discussion

Femoral head is the most common location for AVN and it usually affects the young population [1]. Patient usually

Table 1: Demographics and Distribution of pathologies

Total number of patients	36
Males	26 (72%)
Females	10 (28%)
Cumulative Mean age	38 years
Abnormal X-rays	15 (41.6%)
Normal X-rays	21 (58.4%)
Abnormal MRI	30 (83.4%)
Normal MRI	6 (16.6%)
AVN on MRI	22 (61%)
Unilateral AVN	14 (63.6%)
Bilateral AVN	8 (36.4%)
Total number of femoral heads with AVN	30
Normal X-rays with AVN on MRI	10 (45.5%)
X-rays showing AVN	12 (54.5%)
Other pathologies on MRI	8 (22%)
Hip synovitis	3
Sacroiliitis	2
Early hip osteoarthritis	2
Ilio-psoas bursitis	1

Table 2: Incidence of different stages of femoral head AVN on MRI

Total number of femoral heads with AVN	30
Ficat and Arlet classification	
Grade I	6 (20%)
Grade II	12 (40%)
Grade III	10 (33%)
Grade IV	2 (7%)
Mitchell classification	
Stage A	7 (23%)
Stage B	10 (33%)
Stage C	11 (37%)
Stage D	2 (7%)

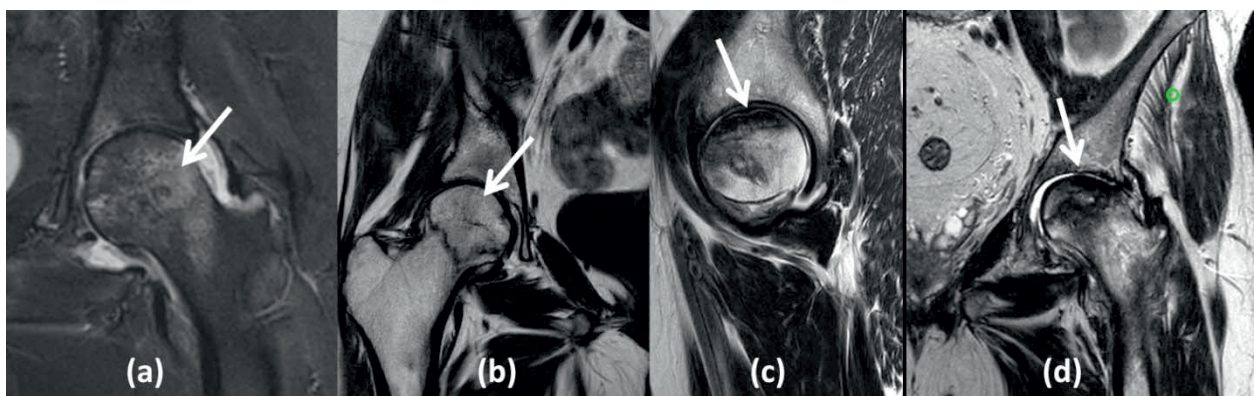


Figure 1: MR Images demonstrating different grades of Ficat and Arlet classification of AVN femoral head. (a) **Grade I:** Diffuse marrow edema in the femoral head and neck (arrow). (b) **Grade II:** Geographical area of signal alteration in subchondral region of femoral head (arrow). (c) **Grade III:** Disruption of the normal contour of the femoral head with cortical collapse (arrow). (d) **Grade IV:** Subarticular collapse of femoral head associated with advanced degenerative changes of hip (arrow).

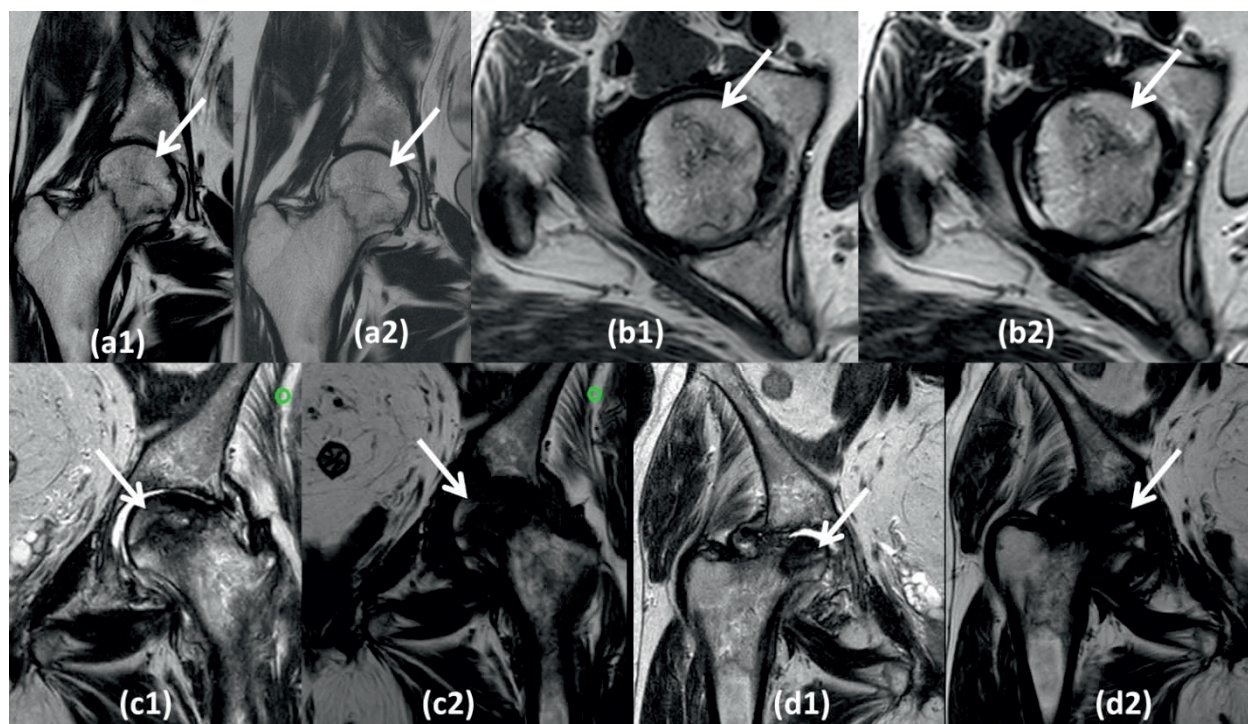


Figure 2: Paired T1 and T2 MR images with arrows demonstrating Mitchell classification of AVN femoral head.
(a1,2) Stage A: Signal similar to fat with normal morphology of femoral head.
(b1,2) Stage B: Signal similar to blood with normal morphology of femoral head.
(c1,2) Stage C: Signal similar to fluid with loss of the normal contour of the femoral head and cortical collapse.
(d1,2) Stage D: Signal similar to fibrosis with advanced degenerative changes of hip.

present with hip pain but it can be asymptomatic in some patients. The exact pathophysiology of AVN is not well understood, but there is a consensus that the cell death found in AVN is related to interruption in the blood supply to femoral head. The common causes include trauma, corticosteroid use, sickle cell disease, alcoholism, thalassemia, radiation, and Caisson's disease [2]. AVN of hip is a debilitating disease and is a common cause for hip arthroplasty in end-stage arthritis in young persons. Early diagnosis of the disease is critical for early intervention and prevention of end-stage secondary arthritis. The treatment of choice for early AVN remains core decompression. Among all the modalities, MRI is promising in early diagnosis and staging of the disease process which finally helps in planning of treatment

In our prospective study of 36 patients, mean age was 38 years which was similar to 38.35 years in the study conducted by Jyoti et al [3]. Eleven patients (30.5%) in our study gave history of alcohol abuse which was similar to 35% in study conducted by Kakaria et al [4]. Six patients (20%) had history of corticosteroid use, One (1) patient has sickle cell disease and 4 patients did not have any attributing cause. Bilateral disease was seen in 63.6% of our patents which was similar to 68% in the study conducted by Jyoti et al [3].

There are different classification systems for staging of AVN of femoral head. Ficat and Arlet classification and Mitchell classification system are two most accepted classifications with good practical implication. According to Ficat and Arlet [5] classification of AVN, Grade I disease revealed diffuse marrow edema in the femoral head, which was seen in 6 femoral heads (20%) in our study [Figure 1a]; Grade II revealed focal geographical area of signal alteration in subchondral region of femoral head (12 femoral heads, 40%) [Figure 1b]; Grade III revealed disruption of the normal contour of the femoral head with eventual cortical collapse (10 femoral heads, 33%) [Figure 1c]; and Grade IV revealed subarticular collapse of femoral head associated with advanced degenerative changes of hip (2 femoral heads, 7%) [Figure 1d]. Thus, Grade II AVN was the most common in our study. Mitchell classification [6] divided AVN to four stages based on MRI signal within the center of the lesion. Stage A has signal similar to fat, which was seen in 7 femoral heads (23%) [Figure 2a (1,2)] in our study; Stage B has signal similar to blood (10 femoral heads, 33%) [Figure 2b (1,2)]; Stage C has signal similar to fluid (11 femoral heads, 37%) [Figure 2c (1,2)]; and Stage D has signal similar to fibrosis (2 femoral heads, 7%) [Figure 2d (1,2)]. Thus, Stage C AVN was the most common in our study. Or study also showed a good correlation

between the two classification systems.

MRI was found to be highly sensitive in the detection of early AVN in our study, i.e., Grade I and Grade II combined 60% and Stage A and Stage B combined 56%. A large number of patients with early AVN on MRI had normal X-rays. Thus we recommend early use of MRI for detection of AVN where there is high clinical suspicion and X-ray is normal. This will lead to early intervention and prevent the disease to progress to end-stage arthritis where arthroplasty is the treatment of choice. MRI also has distinct advantage over other modalities in being radiation free, non-invasive and excellent soft tissue contrast. Staging system of AVN on MRI also further helps in decision making for appropriate treatment. Further imaging studies are needed on AVN hip for prognostication and to measure the treatment outcomes.

Conflict of interest:	All authors declare no COI
Ethics:	There is no ethical violation as it is based on voluntary anonymous interviews
Funding:	No external funding
Guarantor:	Dr. Amit Kumar Sahu will act as guarantor of this article on behalf of all co-authors.

References

1. David S. Levey. AVN of the Hip. MRI Web Clinic. November 2005
2. Ho-Rim Choi et al. Osteonecrosis of the femoral head: diagnosis and classification systems. Current Review in Musculoskeletal Medicine. Sep 2015; 8(3): 210-220.
3. Jyoti Choudhary et al. Magnetic Resonance Imaging in Evaluation of Avascular Necrosis of Femoral Head. International Journal of Scientific Study. October 2019; 7(7): 50-55.
4. Kakaria BH et al. Total hip replacement in avascular necrosis of femoral head. Medical Journal of Armed Forces India. 2005;61:33-5.
5. Ficat RP, Arlet J. Ischemia and Necrosis of Bone. Baltimore, London: Williams and Wilkins; 1980. p. 196
6. Mitchell DG, et al. Femoral head avascular necrosis: Correlation of MR imaging, radiographic staging, radionuclide imaging, and clinical findings. Radiology 1987;162:709-15

