

# Ultrasound Evaluation of Thyroid Nodules and its Pathological Correlation.

B. Mallikarjunappa, Ashish S. R.

Department of Radio-diagnosis, Adichunchanagiri Institute of Medical Sciences,  
BG NAGARA, Mandya District, Karnataka, India

**Abstract:** The purpose of this study was to evaluate morphological features of benign & malignant nodules seen on ultrasound (US). 200 Patients referred to our dept were scanned & individual sonological features were analyzed for the prediction of benignity and malignancy. Individual US morphological features did not show specificity & sensitivity towards our aims. There was overlap of some features like ultrasonographic nodules, irregular margins, hypochoic nodule with intervening halo, nodule with colloid goiter and well defined hypochoic nodules with internal echoes, with well defined borders, and with Iso or avascular nodule had high specificity for benignity. **Conclusion:** Accuracy of individual US morphological features was assessed for their predictiveness towards malignancy and benignity. Patients with multiple US morphological features which had high specificity & sensitivity, should not be biopsied and should be followed up. The US morphological features which were overlapping in terms of malignancy and benignity should be biopsied.

## INTRODUCTION

Thyroid nodules are seen in 15% of adult population. Thyroid masses are more common in females and these may be benign or malignant. Most of them are benign and malignancy is quite low a 5-7%. Evaluation of thyroid masses by conventional radiography is inclusive or limited and is helpful in assessing the retrosternal extension of thyroid, thyroid calcification, lymphnode and distant metastases. Scintigraphy is reserved for only characterization of functional nodules, for staging follicular and papillary carcinoma and staging lymphoma. CT is additional imaging modality for assessing regional and distant metastasis only. MRI has limited role in imaging of thyroid nodules except for staging of thyroid lymphoma. Several studies have been conducted to analyse the sonological features of benignity and malignancy but none of the US morphological features had high specificity and sensitivity. This study was done to evaluate the accuracy of sonological features of benign malignant and nodules and to design and the protocol to be followed for FNAC.

## MATERIAL AND METHODS

Two hundred (200) patients of clinically suspected thyroid nodules, who were referred to our department during the last 2 years, were scanned with 7.5-12MHz transducer.

The following sonological features were studied

- 1.) Location of the nodule,
- 2.) Number, size shape (oval/round)
- 3.) Margins regular/irregular, ill defined (a thyroid nodule is ill defined when more than 50% of its border is not demarcated).
- 4.) Internal contents: solid/cystic/ mixed,
- 5.) Cystic lesions with septations or echogenic foci,
- 6.) Echo texture: hyper/hypo/Isochoic, with reference to remaining thyroid parenchyma.
- 7.) Parenchyma interface: invisible/echogenic rim/hypochoic halo, (halo or Hypochoic rim around a thyroid nodule is produced by a pseudo capsule of fibrous connective tissue, a compressed thyroid parenchyma, and chronic inflammatory infiltrates).
- 8.) Calcification absent: present a) Egg shell. b) Course. c) Micro calcification (thyroid micro calcification are psammoma bodies, which are 10-100µm round laminar crystalline calcific deposits and appears as punctuate Hyperechoic foci without acoustic shadowing coarse calcification b) more than 2cm in size, irregular in shape causes acoustic shadowing, a) egg shell calcification or peripheral ring like echogenic lesion with acoustic shadowing.
- 9.) Posterior sound transmission: Enhancement/shadow/no change.
- 10.) Vascularity-intrinsic hyper vascularity/diffused hyper vascularity/peri nodal vascularity/avascularity (intrinsic vascularity is defined as the flow in the central part of the tumor greater than that in the surrounding

thyroid parenchyma. Peri nodal vascularity is defined as the presence of vascularity around at least 25% of the circumference of the nodule.)

11.) Muscle and vascular invasion: present/absent.

12.) Cervical Lymphadenopathy: present/absent

13.) Distant metastasis: present/absent.

Results of the examination were interpreted on the basis of these findings and diagnosis was proposed after considering history and physical examination & FNAB.

The results were given as the lesion is solid, cystic or mixed nodules.

1.) Criteria for benign simple cyst:

- Anechoic lesion.
- Round or oval shape.
- Posterior acoustic enhancement.

2.) Criteria for hemorrhagic cyst:

- Rapid growing in nature.
- Cystic lesion with internal echoes.
- Fluid-fluid level which may change with the position of the patient.
- Multiple thick septations if present.

3.) Criteria for colloid goiter (adenomatous) with cystic degeneration:

- Purely anechoic lesion.
- Anechoic lesion with internal echoes.
- Fluid-fluid level which may change with position of the patient.
- Irregular margins.
- Bright echogenic foci with comet tail artifacts
- Multiple thin septations.

4.) Nodule having both cystic and solid portion is labeled as mixed.

5.) Nodules were categorized as benign and malignant based on morphological features of ultrasound & FNAB findings.

## RESULTS

200 patients referred to our department with clinically palpable nodule were scanned. Age range of our study was between 11-50 years, youngest patient was 20 years old female and eldest was 70 years old female. Majority of the cases affected were in the age group of 21-40 years. Of the 200 pts in our study group females constituted n=168 (84%) and males n=32 (16%). Thyroid masses of our study were categorized sonologically into cystic n=50 (25%), solid n=93 (47%) and mixed n=57 (28%).

**Table 1:** Sonographic Features of Different Types of Cystic Lesions [FNAC Proved]

Sonographic Feature	Goiter with cystic degeneration	Papillary Carcinoma (Cystic)	Hemorrhagic cyst
Shape			
Round	4		2
Oval	25		
Irregular	16	3	
Margins			
Regular	27	3	2
Irregular	18		
Echo texture			
Hypo	40	1	
Hyper			
Iso			
Mixed	5	2	2
Calcification	(Eggshell10+1 coarse)	(Micro calcification)2	0
Intra cystic septations	7	0	0
Hypo echoic HALO	0	0	0
Vascularity	Pnv 40	Inv 2	
Lymphadenopathy	0	2	0
Distant metastasis	0	0	0
<b>Total</b>	<b>45</b>	<b>3</b>	<b>2</b>

Pnv-peripheral vascularity

Inv-internal vascularity

**Correspondence:** Dr. B.Mallikarjunappa, Associate professor,  
Department of Radio-diagnosis, Adichunchanagiri Institute of Medical  
Sciences, BG NAGARA, Mandya District, Karnataka-571448, India  
e-mail: drmallikarjunappa@gmail.com

**Table 2: Sonographic Features of Different Types of Solid Lesions [FNAC Proved]**

Sonographic Feature	Colloid Goiter	Follicular Adenoma	Papillary Carcinoma	Hashimoto's thyroiditis
Shape				
Round	0	11	0	37
Oval	5	18	4	3
Irregular	2	1	12	0
Margins				
Regular	4	23	2	40
Irregular	3	7	14	0
Echo texture				
Hypo	2	5	14	35
Hyper	3	2	0	3
Iso	2	23	0	2
Mixed	0	0	2	0
Calcification	7	0	13	0
	ESC 5 COA C 2		MICRO C10 CAO 3	
Hypo echoic HALO	2	25	2	0
Vascularity	Pnv 5	20	Inv 14	35
Lymphadenopathy	0	0	14	0
Distant metastasis	0	0	0	0
<b>Total</b>	<b>7</b>	<b>30</b>	<b>16</b>	<b>40</b>

ESC-egg shell calcification COA-coarse calcification. MICRO-microcalcification.

**Table 3: Sonographic Features of Various Mixed Lesions [FNAC Proved]**

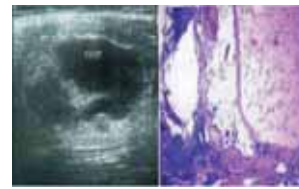
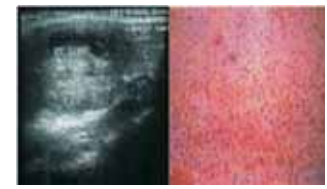
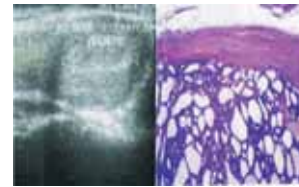
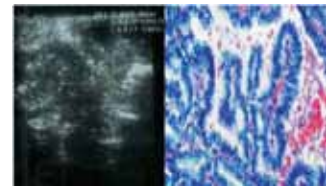
Sonographic Feature	Colloid Goiter	Follicular Adenoma	Papillary Carcinoma	Hashimoto's thyroiditis	Follicular Carcinoma
Shape					
Round	39	2	1	0	1
Oval	9	2	0	0	0
Irregular	0	1	1	0	1
Margins					
Regular	41	3	0	0	1
Irregular	7	2	2	0	1
Echo texture					
Hypo	28	2	0	0	2
Hyper	7	2	0	0	0
Iso	4	1	0	0	0
Mixed	9	0	2	0	0
Calcification	27	0	2	0	0
	ESC 17 COAC10				
Intra cystic septations	7	0	0	0	0
Hypo echoic HALO	5	0	1	0	0
Vascularity	Pnv 35		2		2
Lymphadenopathy	0	0	2	0	0
Distant metastasis	0	0	0	0	0
<b>Total</b>	<b>48</b>	<b>5</b>	<b>2</b>	<b>0</b>	<b>2</b>

**Table 4: Distribution of Malignant and Benign Lesions**

Type of lesion	Benign	Percentage	Malignant	Percentage	Total
Cystic	47	92.85%	3	7.15%	50
Solid	77	83.01%	16	16.9%	93
Mixed	53	93%	4	6.25%	57
<b>Total</b>	<b>177</b>	<b>88.4%</b>	<b>23</b>	<b>11.5%</b>	<b>200</b>

**Cystic Lesions:** 200 cases were sonologically diagnosed into (a) cystic lesions namely colloid goiter with cystic degeneration n=46, (b) cystic papillary carcinoma n=2, and (c) hemorrhagic cyst n=2. FNAB proved 46 cases of colloid goiter with cystic degeneration 45 proved to be correct, 2 out of 2 cases of hemorrhagic cysts proved to be correct, 2 cases of cystic papillary carcinoma were proved to be correct. But 1 case of colloid goiter with cystic degeneration had cystic papillary carcinoma. Majority of Colloid goiter with cystic degeneration had oval in shape with regular margin, of Hypoechoic and only 5 were mixed echogenic. Calcification was seen in 2 cases and intracystic septations was seen in 7 cases. One case of colloid goiter with internal hemorrhage of oval shape, irregular margin with internal contents was proved to be cystic papillary carcinoma. Both the cases of cystic papillary carcinoma had calcification and metastatic Lymphadenopathy. Among cystic lesions 47(93%) were benign and 3(7%) were malignant.

**Solid Lesions:** Sonologically diagnosed solid lesions were of 1 colloid

**Fig. 1: Goiter with cystic degeneration****Fig. 2: Goiter with internal haemorrhage****Fig. 3: Follicular adenoma****Fig. 4: Papillary carcinoma**

goiter n= 19, 2 follicular adenoma n= 23, 3 papillary carcinoma n= 14, 4 Hashimoto's thyroiditis n= 37, and FNAC proved in 1- 7, in 2-30, in 3-16, in 4-40. Sonologically diagnosed 7 cases of colloid goiter were proved to be follicular adenoma, 2 cases as papillary carcinoma and 3 as Hashimoto's thyroiditis. Among 93 cases of solid lesions 37 cases had Hashimoto's thyroiditis, 35 cases showed diffuse enlargement and 2 cases showed hyperechoic nodules with hypoechoic halo, 35 cases were hypoechoic. Hyper vascularity was noted in all the cases. Among follicular adenoma (n=30), majority were oval in shape with regular margins; hypoechoic halo was observed in 70% of cases. Among 7 cases of colloid goiter, 5 cases had oval shape, 3 were hypoechoic and 2 cases showed hypoechoic halo. Among solid lesions, 83% were benign and 17% were malignant.

**Mixed Lesions:** Our study of sonologically diagnosed 57 mixed lesions comprised 1 Goiter in cystic degeneration n=53, 2 follicular adenoma n=2, 3 papillary carcinoma n=2, 4 follicular carcinoma n=0 and FNAC proved in 1-48, in 2-05, in 3-02, in 4-02. 3 cases of goiter with cystic degeneration were proved to be follicular adenoma and 2 cases as follicular carcinoma. Out of 5 cases of goiter cystic degeneration 3 were proved to be papillary carcinoma and 2 were proved to be follicular carcinoma.

**Calcification:** Amongst cases of colloid goiter (n=100), follicular adenoma (n=35), papillary carcinoma (n=18), follicular carcinoma (n=2), calcification was seen in 9(9%), 0(0%), 16(91%), 0(0%), respectively.

**Hypoechoic Halo:** Amongst cases of colloid goiter (n=100), 7(7%) cases showed hypoechoic halo; follicular adenoma (n=35), 20(70%) cases showed hypoechoic halo; papillary carcinoma (n=18), 2(6.48%) cases showed hypoechoic halo.

**Vascularity:** In our study, majority of follicular adenoma and Hashimoto's thyroiditis showed increased vascularity, colloid goiter showed peripheral vasculature and papillary carcinoma showed internal vasculature.

**Micronodulation:** In our study of 200 cases, 37 were diagnosed as Hashimoto's thyroiditis. 35 cases (95%) showed micronodulation and 2 cases showed macronodulation. All cases of papillary ca had cervical Lymphadenopathy.

**Benign vs Malignant:** In our study of cystic lesion, 92.85% were benign and 7.15% were malignant. Among solid lesion, 83% were benign and 13% were malignant. Among mixed lesion 94% were benign and 6% were malignant. Total benign lesions constituted 88% and malignant lesions constituted 12%. Thus sensitivity of ultrasound in diagnosing cystic lesion was 97% and false positive were 83%.

## DISCUSSION

In our study of thyroid nodules, the occurrence among males and females was 15.9% and 84.1% respectively. This correlated with Solbiati et al<sup>1</sup>

and Kimoto et al<sup>12</sup> 90% and 10%, respectively. Our study age incidence correlates to Kimoto et al<sup>12</sup> and Wunderbaldinger P et al<sup>7</sup>, where there incidences range between 20-27 years.

Accuracy of our results with reference to benignity and malignancy of cystic lesions was 92.8% and 7.1%; correlates with observation of Chan BK et al<sup>17</sup>, in which 6% of the lesions were malignant among cystic lesions. Among solid lesions 83% were benign and 17% were malignant; this correlates with the finding of Solbiati et al<sup>1</sup>. Among mixed lesions, 75% were benign nodules and 25% were malignant nodules. Calcification was found in 8.75% in colloid goiter and 91.25% in papillary carcinoma. The statistical analysis of the data regarding irregular margins hypoechoogenicity, vascularity, coarse/micro calcification did not correlate with other studies<sup>12</sup>. However, majority of papillary carcinoma cases had micro calcification and lymph node metastasis.

## CONCLUSION

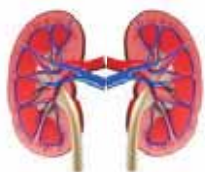Individual sonological features such as calcification, hypoechoic, irregular margins and vascularity were absent in some of the FNAC proved malignant nodules and were present in few of benign nodules.

Our study revealed that features like hypochoic nodule with micro calcification, coarse calcification in a hypochoic nodule, well marginated oval shape nodule with hypochoic halo, irregular solid nodule with hypervascularity with local invasion, distant lymph node metastasis are more specific for malignancy or are potentially malignant and should undergo FNAC<sup>13</sup>. Nodules of irregular margins of hypochoic, with intervening halo, nodule with colloid goitre, well defined hypochoic nodules with internal echo's, with well defined borders, with Iso or avascular nodule need not to be biopsied, should be left alone and followed

up<sup>14</sup>. Fine needle aspiration biopsy under US guidance should be considered as the most reliable diagnostic procedure for evaluation of thyroid nodules and has a low rate of complications.

## REFERENCES

1. Solbiati L, Cioffi V, Ballarati E: Contribution of color -flow mapping to the differential diagnosis of the thyroid nodules, RSNA meeting, 1992.
2. Ahuja A, Chick W, and King W et al: Clinical Significance of the comet tail artifact in thyroid ultrasound, J Clin Ultrasound 24: 129-33, 1996.
3. Yokazawa T, Fukata S, Kanji K et al: Thyroid cancer detected by ultrasound guided FNAC, World J Surgery 20,848-53, 1996.
4. Lin JD, Huang BY, Weng HF et al: thyroid ultrasonography with fine-needle aspiration cytology for the diagnosis of thyroid cancer, J Clin Ultrasound 25: 111-8, 1997.
5. Wiest PW, Hartshorne MF, Inskip PD et al: thyroid palpation versus high-resolution thyroid ultrasonography in the detection of nodules, J Ultrasound Med 17(8):487-96, 1998.
6. Ganesan S: Pictorial Essay: sonographic patterns of cervical nodal disease in papillary thyroid carcinoma, Ind J Radio Image 10(1):25-28, 2000.
7. Wunderbaldinger P, Harsinghani MG, Hahn PF et al: Cystic lymph node metastases in papillary thyroid carcinoma, AJR 178:693-7, 2002.
8. Screaton NJ, Berman LH, and Grant JW: US-guided core-needle biopsy of the thyroid gland, Radiology 226:827-32, 2003.
9. Wienke JR, Chong WK, Fielding JR et al: Sonographic features of benign thyroid nodules, J Ultrasound Med 22:1027-31, 2003.
10. Schliemann U, Avenhaus W, Konturek JW et al: Relationship of clinical features and laboratory parameters of thyroid echogenicity measured by standardized grey scale ultrasonography in patients with Hashimoto's thyroiditis, Med Sci Monit 9(4): MT 13-7, 2003.
11. Seiberling KA, Dutra JC, Grant T et al: Role of intrathyroidal calcification detected on ultrasound as a marker of malignancy, Laryngoscope 114(10):1753-7, 2004.
12. Kimoto et al: The efficiency of performing FNAC following mass gaining for thyroid tumors to avoid unnecessary surgery, surge today 29(9) 880-3, 1999.
13. John A et al: pattern recognition of benign nodules at ultrasound of thyroid: which nodules left alone AJR 2009, 193:1, 207-213
14. Jenny K. Hoang et al: Radio graphics may 2007 27, 847-860.



## Our Key Products

**Oriva**  
Nephrocare

**RENOPHILUS**<sup>TM</sup>  
Probiotic 90Billion CFU

**KETODEL**<sup>TM</sup>  
Alpha Ketoanalogue Tablet

**Q-TINE**<sup>TM</sup>  
Coenzyme Q<sub>10</sub> + L-Carnitine

**GLUTAFIT**<sup>TM</sup>  
L-glutamine 10g+Vit. A 5000 IU+Vit. E 120 IU

**AVRON**<sup>TM</sup>  
Injection Iron Sucrose 20mg/ml

**ORITROL**<sup>TM</sup>  
Calcitriol 0.25 mcg

**RENFOL**<sup>TM</sup>  
Folic Acid 10mg Ferrous ascorbate  
100mg+methylcobalamin 500mg  
+B complex

**ORISIS**<sup>TM</sup>  
Sodium bi carbonate 500mg

**ORIPRO**<sup>TM</sup>  
High Protein Formula 61gm/serving

For Further Information:  
[www.orivalifesciences.com](http://www.orivalifesciences.com)  
Helpline No. : 99530 45902

**ORIVA LIFESCIENCES PVT. LTD.**  
206 National Arcade, Plot No. 4,  
LSC Ghazipur, Delhi-110096