

Staging and Pathology of Breast Cancer - Recent Advances

S.V.S.R. KRISHNA

Department of Surgery, Sitaram Bharatia Institute of Science & Research, New Delhi, India

Abstract: Significant developments in the field of early detection, diagnosis, management and standardization of multimodality therapies have necessitated the need for updating the staging system for breast cancer. These revisions essentially represent a 'fine tuning' of the initial judgment that tumour size, lymph node status, presence of distant metastases are significant prognostic factors and likely in the future histological grading will join this group of independent markers

Keywords: Breast cancer, staging, lymph nodes, metastases.

Introduction

Breast carcinoma is a devastating illness both physically and emotionally, affecting thousands of women, with special preponderance in the urban population. Comprehensive breast cancer management involving multimodality therapies which include surgery, neo adjuvant chemotherapy, radiation, immunotherapy, hormonal therapy is a must, to achieve optimum cure and survival rates. The foundation to decide the optimum therapy or combination therapy depends on staging the disease. Proper staging of breast cancer assists the treating clinician in making appropriate treatment decisions and in evaluating the results of different treatment strategies. The staging system for carcinoma of the breast applies to infiltrating breast carcinoma, including micro invasive and in situ carcinomas. Microscopic confirmation is mandatory and the histological type and grade of the carcinoma should be recorded.

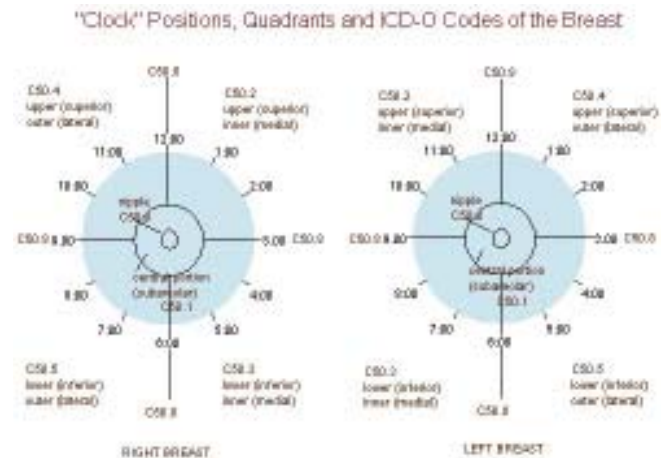
The American Joint Committee on Cancer (AJCC) staging system provides a strategy for grouping patients with respect to prognosis. Therapeutic decisions are formulated in part according to staging categories but primarily according to tumor size, lymph node status, estrogen-receptor and progesterone-receptor levels in the tumor tissue, menopausal status, and the general health of the patient

Anatomy

Primary Site

Breast tissue extends from below the collarbone to the level of the sixth or seventh rib, and from the breastbone to the underarm (axilla). In the center of the breast is the nipple, or mammilla, and areola (circular area around the nipple). Montgomery's glands, located around the edge of the areola, release a fatty substance that protects the nipples during nursing. The breasts of an adult woman are milk-producing, tear-shaped glands. They are supported by and attached to the front of the chest wall on either side of the breast bone or sternum by ligaments. They rest on the major chest muscle, the pectoralis major. The breast has no muscle tissue. A layer of fat surrounds the glands and extends throughout the breast. The breast is responsive to a complex interplay of hormones that cause the tissue to develop, enlarge and produce milk. The three major hormones affecting the breast are estrogen, progesterone and prolactin, which cause glandular tissue in the

breast and the uterus to change during the menstrual cycle. Each breast contains 15 to 20 lobes arranged in a circular fashion. The fat (subcutaneous adipose tissue) that covers the lobes gives the breast its size and shape. Each lobe is comprised of many lobules, at the end of which are tiny bulb like glands, or sacs, where milk is produced in response to hormonal signals. Ducts connect the lobes, lobules, and glands in nursing mothers. These ducts deliver milk to openings in the nipple. The areola is the darker-pigmented area around the nipple.



Chest wall

The chest wall includes the ribs, intercostals muscles, and serratus anterior muscle; the pectoral muscles are not included.

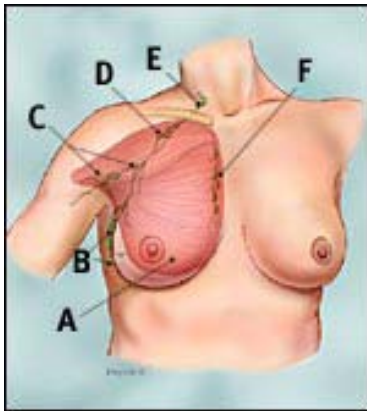
Regional Lymph nodes

The breast lymphatics drain by way of three major routes – axillary, transpectoral and internal mammary. For staging purposes intramammary nodes are classified as axillary and supraclavicular nodes as regional group.

The regional nodes are classified as

1. Axillary – Ipsilateral – Rotter's nodes and lymph nodes along the axillary vein and its tributaries and are divided into the following levels –
 - a) Level I - Lymph nodes lateral to the lateral border of pectoralis minor muscle.
 - b) Level II – Lymph nodes between the lateral and medial borders of the pectoralis muscle and the Rotter's nodes.

- c) Level III – Lymph nodes medial to medial border of pectoralis minor muscle and originally classified as apical group.
2. Internal Mammary - Ipsilateral – lymph nodes along the edge of the sternum in the endothoracic fascia.
3. Supraclavicular - lymph nodes in the supraclavicular fossa. Adjacent lymph nodes outside of this triangle are considered to be lower cervical nodes (M1).



Lymph node areas adjacent to breast area

- A Pectoralis major muscle
- B Axillary lymph nodes: levels I
- C Axillary lymph nodes: levels II
- D Axillary lymph nodes: levels III
- E Supraclavicular lymph nodes
- F Internal mammary lymph nodes

Metastatic Sites

The four major sites of involvement are bone, lung, brain and liver, but tumor cells are capable of metastasizing to many other sites.

Rules of classification.

Clinical staging

This includes physical examination, with careful inspection and palpation of the skin, breast and lymph nodes, imaging and pathologic examination of the breast and other relevant tissues to establish the diagnosis. Imaging findings are considered as part of staging, only if they are collected within 4 months of diagnosis in the absence of disease progression or through completion of surgery. Imaging and surgical findings obtained after a patient has been treated with neo adjuvant chemotherapy, hormonal therapy, immunotherapy or radiation therapy are not considered elements of initial staging

Pathologic Staging

Pathologic staging includes all data used for clinical staging plus data from surgical exploration and resection as well as pathologic examination of the primary carcinoma, regional lymph nodes and metastatic sites. If there is only microscopic but no macroscopic involvement at the margin, it is classified as pT; whereas if there is tumor in the margin of resection it would be pTX (total extent cannot be assessed). If the primary tumor is invasive, resection of at least the level I axillary lymph nodes should be done and should include at least six nodes. Alternatively Sentinel Lymph node biopsy can be done. Histological types which do not require a lymph node biopsy are : pure tubular carcinoma < 1 cm, pure mucinous carcinoma < 1 cm and micro invasive carcinoma. Cancerous nodules in the axillary fat adjacent to the breast, without histological evidence in lymph nodes are classified as regional lymph nodes (N). if surgery occurs after the patient has

received neo adjuvant chemotherapy, hormonal therapy, immunotherapy or radiation therapy, the prefix “y” should be used.

TNM Classification

T – Primary Tumor

Determining tumor size – the clinical measurement is based on physical examination or imaging such as mammography or ultrasound. The pathologic tumor size is a measurement of only the invasive component and the size is assessed before any tissue is removed for special studies, such as estrogen receptors.

Tis classification - carcinoma *in situ* with no evidence of an invasive component is classified as Tis, cases of ductal carcinoma-*in-situ* and cases with both ductal and lobular component are classified as Tis (DCIS). Lobular carcinoma *in situ* is designated as Tis (LCIS), Paget’s disease of the nipple without an associated tumor is classified as Tis (Paget’s) and Paget’s disease with a demonstrable mass or invasive component is classified as according to the tumor or invasive component.

Microinvasion of breast carcinoma – microinvasion is the extension of cancer cells beyond the basement membrane into the adjacent tissues with no focus more than 0.1 cm in greatest dimension. The size of only the largest focus is used for classification.

Multiple Simultaneous Ipsilateral Primary cancers – in infiltrating, macroscopically measurable multiple simultaneous ipsilateral primary carcinomas, the following guidelines are used

- a) Use the largest primary carcinoma to classify T.
- b) Record that this is a case of multiple simultaneous primary carcinomas.

Simultaneous Bilateral Breast Carcinoma – each carcinoma is staged as a separate primary carcinoma in a separate organ.

Inflammatory Carcinoma – a clinicopathologic entity characterized by diffuse erythema and edema (peau d’orange) of the breast, often without an underlying palpable mass and the clinical presentation is due to tumor emboli within the dermal lymphatics. It is classified as T4d

Skin changes – dimpling of skin, nipple retraction, or any other skin change except those under T4b or T4d may occur, without changing the classification.

N - Regional Lymph Nodes

Macrometastasis – clinically apparent is defined as detected by imaging studies, excluding lymphoscintigraphy or by clinical examination or grossly visible pathologically. A case in which classification is designated purely by sentinel lymph node biopsy is suffixed as “(sn)” e.g. – pN1 (sn).

Isolated Tumor Cells and Micrometastases – Isolated Tumor Cells (ITCs) are defined as single cells or small clusters of cells, not greater than 0.2 mm in largest dimension, usually with no histological evidence of malignant activity. If an additional immunohistochemical examination was made, it should be designated as pN0 (i-) or pN0 (i+). Macrometastases are defined as tumor deposits greater than 0.2 mm and greater than 2 mm in the largest dimension. If histologically and immunohistochemically

negative lymph nodes are examined using molecular methods (reverse transcriptase-polymerase RT-PCR), lymph nodes are classified as pN0 (mol-) or pN0 (mol+), as appropriate.

M - Distant Metastasis

A negative clinical history and examination are sufficient to designate a case as M0, extensive imaging and other testing is not required. Positive supraclavicular lymph nodes are now classified as N3 and not as M1.

Defintion of TNM

T – Primary Tumor – definitions for classifying primary tumor are same for clinical and pathological classification.

TX	Primary tumor cannot be assessed.
T0	No evidence of primary tumor.
Tis (DCIS)	Ductal Carcinoma <i>is situ</i>
Tis (LCIS)	Lobular Carcinoma <i>is situ</i>
Tis (Paget's)	Paget's disease of the nipple with no tumor.
T1	Tumor 2 cm or less in greatest dimension,
T1mic	Microinvasion 0.1 cm or less in greatest dimension.
T1a	Tumor more than 0.1 cm but not more than 0.5 cm in greatest dimension.
T1b	Tumor more than 0.5 cm but not more than 1 cm in greatest dimension.
T1c	Tumor more than 1 cm but not more than 2 cm in greatest dimension.
T2	Tumor more than 2 cm but not more than 5 cm in greatest dimension.
T3	Tumor more than 5 cm in greatest dimension.
T4a	Extension to the chest wall, not including pectoralis muscle.
T4b	Edema, including peau d'orange, ulceration of skin, or satellite nodules to the same breast.
T4c	Both T4a and T4b.
T4d	Inflammatory carcinoma.

N – Regional Lymph Nodes

Clinical

NX	Regional lymph nodes cannot be assessed.
N0	No regional lymph nodes metastasis.
N1	Metastasis to movable Ipsilateral axillary lymph nodes.
N2a	Metastasis to Ipsilateral axillary lymph nodes fixed to one another or to other structures.
N2b	Metastasis only in clinically apparent ipsilateral internal mammary nodes and in the absence of clinically evident axillary lymph nodes.
N3a	Metastasis in Ipsilateral infraclavicular lymph nodes.
N3b	Metastasis in Ipsilateral internal mammary and axillary lymph nodes.
N3c	Metastasis in Ipsilateral supraclavicular lymph nodes.

Pathologic

pNX	Regional lymph nodes cannot be assessed.
pN0	No regional lymph node metastasis histologically.
pN0 (i-)	No regional lymph node metastasis histologically, negative IHC.
pN0 (i+)	No regional lymph node metastasis histologically, positive IHC.
pN0 (mol-)	No regional lymph node metastasis histologically,

pN0 (mol+)	negative molecular findings. No regional lymph node metastasis histologically, positive molecular findings.
pN1mi	Micrometastasis greater than 0.2mm but none greater than 2.0mm.
pN1a	Metastasis in 1 – 3 axillary lymph nodes.
pN1b	Metastasis in internal mammary nodes with microscopic disease detected by SLNB but not clinically apparent.
pN1c	Metastasis in both 1 – 3 axillary and internal mammary lymph nodes.
pN2a	Metastasis in 4 – 9 axillary lymph nodes.
pN2b	Metastasis in clinically apparent internal mammary nodes in the absence of axillary node involvement.
pN3a	Metastasis to 10 or more axillary lymph nodes or to infraclavicular lymph nodes.
pN3b	Metastasis in clinically apparent Ipsilateral internal mammary nodes in the presence of 1 or more axillary nodes or, in more than 3 axillary lymph nodes and in internal mammary nodes detected by SLNB but not clinically apparent.
pN3c	Metastasis in supraclavicular lymph nodes.

M – Distant Metastases

MX	Distant metastasis cannot be assessed.
M0	No distant metastasis.
M1	Distant Metastasis – bone (OSS), lung (PUL), brain (BRA), liver (HEP)

Staging

Stage designation may be changed if post-surgical imaging studies reveal the presence of distant metastases, provided that the studies are carried out within 4 months of diagnosis in the absence of disease progression and provided that the patient has not received neo adjuvant therapy

Simplified Staging of Breast Cancer

Stage	Tumor Size	Lymph node involvement	Metastasis
I	Less than 2 cm	No	No
II	2-5 cm	No or in same side breast	No
III	Greater than 5 cm	Yes or in same side breast	No
IV	Not applicable	Not applicable	Yes

Detailed Staging

Stage	Tumor Size	Lymph node involvement	Metastasis
Stage 0	Tis	N0	M0
Stage I	T1	N0	M0
Stage IIA	T0	N1	M0
	T1	N1	M0
	T2	N0	M0
Stage IIB	T2	N1	M0
	T3	N0	M0
Stage IIIA	T0	N2	M0
	T1	N2	M0
	T2	N2	M0
	T3	N1	M0
	T3	N2	M0
Stage IIIB	T4	N0	M0
	T4	N1	M0
	T4	N2	M0
Stage IIIC	Any T	N3	M0
Stage IV	Any T	Any N	M0