

QUIZ-IMAGES IN MEDICINE

Kamlender Singh

Senior Consultant, Department of Dermatology, Sir Ganga Ram Hospital, Rajinder Nagar, New Delhi, India.

CASE 1:IMAGE1

A 7 yr old, female having few ill-defined, patches of mild scaling, some with sparse hair. Occasional small round bald patch. Few black dots and tiny stumps of hair in an occasional area.

Your diagnosis?

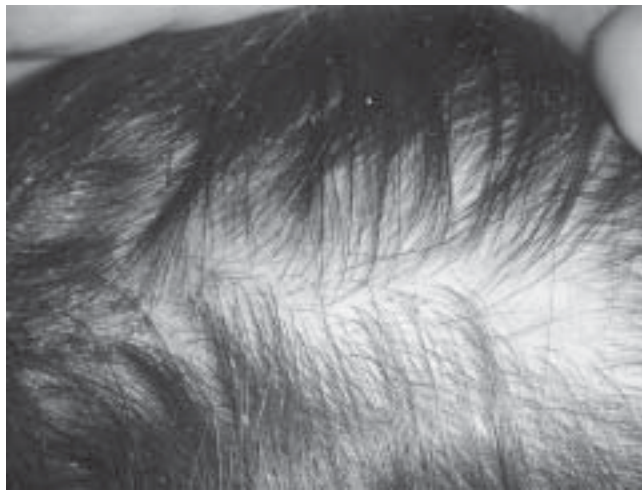

Image 1

CASE 2:IMAGE2

A 15 yrs old, female single, 2 cm in size, erythematous, well defined, irregular, plaque with uneven surface, mild scaling and 2 scabs, over the lateral surface, of the right upper arm for 8 months. Asymptomatic. No other complaints. Systemic examination NAD. Your diagnosis?

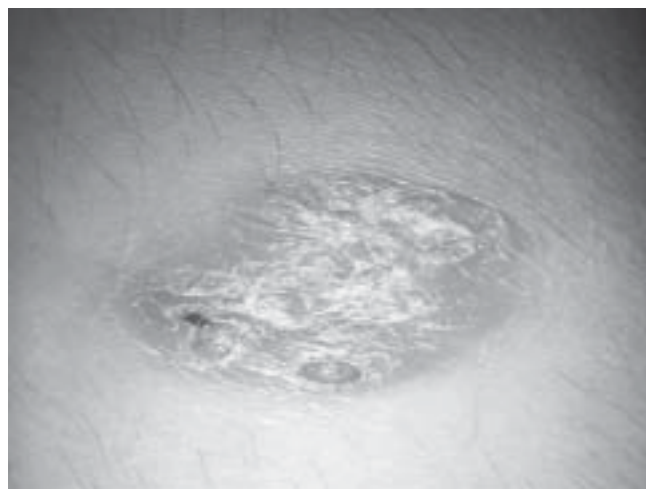



Image 2



With Best Compliments

From *Rinon* Division

Life
LIFE is PRECIOUS
WE CARE
for the ESSENCE of life

AMINOS

(Dialysis Sparing Amino
Acid Tablets)

K-STRYN

(Calcium Polystyrene Sulfonate
15g Sachet)

LAZON

(Metolazone 2.5mg /
5mg Tablets)

LYOTAZ

(Lyophilized Piperacillin Sodium,
Tazobactam Sodium 2.25g / 4.5g Vials)

MPENEM

(Meropenem 0.5g / 1g Vials)

MYOTEC

(Mycophenolate Mofetil
250mg / 500mg Tablets)

MYOTEC-S

(Mycophenolate Sodium
180mg / 360mg Tablets)

PICOSPORIN

(Cyclosporine 25mg / 50mg / 100mg Softgel Caps.,
& 1ml / 5ml Amp., 50ml Oral Solution)

TACROTEC

(Tacrolimus 0.5mg / 1mg /
5mg Capsules)

THIOPRESS

(Azathioprine 50mg Tablets)

UNIRAUT

(Iron Sucrose 2.5ml/50mg
& 5ml/100mg Amp.)

UNIPRAZ

(Prazosin HCL
1mg / 2mg Tablets)

UNITERAZ

(Terazosin HCL
1mg / 2mg / 5mg Tablets)

VANCO-L

(Lyophilized Vancomycin HCL
500mg / 1g Vials)

For further information, please contact :

UNITED BIOTECH (P) LIMITED

Bagbania, Baddi-Nalagarh Road, Distt. Solan (HP) - 174 101
E-mail : ubpl@vsnl.com ; Website : www.unitedbiotechindia.com