

ANSWERS

CASE 1

Ans.: Diagnosis: *T. capitis*.

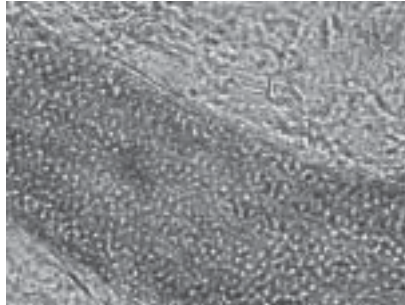


Image 1a: (KOH Mount 40X) Arthroconidia invading the interior of the hair shaft with intact cuticle

CASE 2

Ans.: Diagnosis: Lupus vulgaris.



Image 2a : (100X H&E) necrosis with granuloma with and giant cells

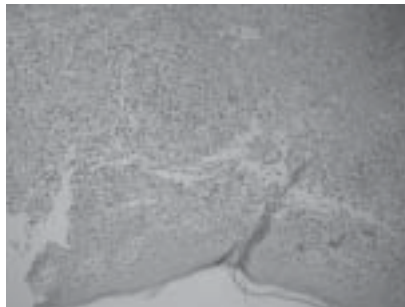


Image 2b: (200XH&E): Epidermis with upper dermis showing epitheloid cell granuloma and extensive necrosis



Image 2c: (400X H & E) Deep dermis inflammation with epitheloid cell granulomas with and central necrosis



Complete Nephro Portfolio

DIALYSIS PORTFOLIO

Epofit
Epoetin Alfa 1000 IU/ml Solution

FE-10
Iron Sucrose Injection

Acutrol
Sevelamer HCl 800mg & 400mg Tablets

TOR
Torsemide 100 mg Tablets

Zalat
Zalcitabine 0.25 g Tablets

Lonitab
Lisinopril 10mg & 20mg Tablets

TRANSPLANT PORTFOLIO

Mycofit-S
Mycophenolate Sodium 360 mg Tablet

Mycofit
Mycophenolate Mofetil 500 mg

Takfa
Tacrolimus 0.1 mg, 1 mg & 5 mg Capsule

INTAS

INTAS PHARMACEUTICALS LTD.

Clinical Centre, Off. Nanyang Bridge, Ashram Road, Ahmedabad - 380 009, INDIA
Tel.: +91-79-25576855 Fax: +91-79-25576935 Email: personal@intaspharma.com