

Anatomy of the Pelvic Floor and Anal Sphincters.

Sneh Agarwal

Department of Anatomy, Lady Hardinge Medical College, New Delhi, India.

Abstract: The pelvic floor is a striated muscular structure providing enclosure to the bladder, uterus, and rectum. It plays significant role in storage and evacuation of urine and stool. This article reviews the anatomy of the anal sphincters and the pelvic floor. The internal and external anal sphincters are responsible for maintaining faecal continence at rest and when continence is threatened, respectively. Defecation is a somato-visceral reflex regulated by dual nerve supply (i.e. somatic and autonomic) to the ano-rectum. The net effects of sympathetic and cholinergic stimulation are to increase and reduce anal resting pressure, respectively. Faecal incontinence and functional defecatory disorders may result from structural changes and/or functional disturbances in the mechanisms of faecal continence and defecation.

INTRODUCTION

Pelvic floor is a funnel or dome-shaped muscular sheet made up of striated muscle which is placed such that it encloses and supports the urinary bladder, uterus and rectum along its midline hiatuses. Pelvic diaphragm forms the inferior boundary of abdominopelvic cavity extending from pubic symphysis anteriorly to coccyx posteriorly and between two pelvic sidewalls. It is responsible for storing and voiding of urine and feces through somatovisceral reflexes.

ANATOMY

Pelvic floor

Pelvic floor is made up of a number of muscles, which are further organized in superficial and deep parts. Even though controversy exists as regarding the nomenclature, the superficial muscles include external anal sphincter, perineal body and transverse perinei muscles. The deep pelvic floor muscles (anatomic pelvic floor) include four major muscles namely pubococcygeus, ileococcygeus, ischiococcygeus and puborectalis. Caudal extension of the circular layer of smooth muscle of rectum into anal canal forms the internal anal sphincter (IAS) and the extension of longitudinal layer of smooth muscle of rectum forms the external anal sphincter (EAS) of the anal canal. (Fig. 1)

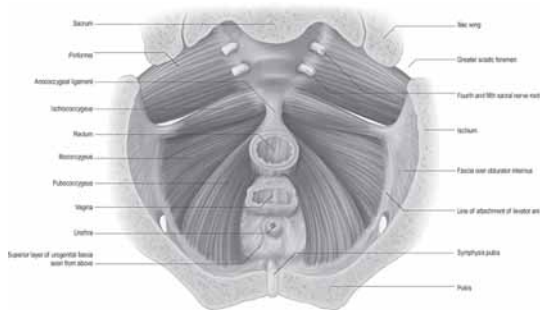


Figure 1: Muscles of the Pelvic Floor

The deep muscles also known as the levator ani muscle originate from the pectinate line of pubic bone and the fascia of obturator internus muscle and are inserted into coccyx. Holl¹ a German anatomist first described that some pubococcygeus muscle fibers looped around rectum and formed “puborectalis” or “sphincter recti”. Together pubococcygeus, puborectalis and puboperineal muscles are

collectively called “pubovisceralis muscle”^{2,3,4}. Lawson described insertions of pubovisceralis muscle into urethra, vagina, perineal body and anal canal. He named them pubourethralis, pubovaginalis, puboperinealis and puboanalis respectively and they basically provided support to visceral organs.

Rectum

The rectum is continuation of sigmoid colon at the level of third sacral vertebra upto the upper end of anal canal. At the beginning rectum is of similar caliber as sigmoid colon, while its lower part is dilated as rectal ampulla. Rectum is devoid of sacculations, appendices epiploicae or mesentery. The taenia blend about 5 cm above rectosigmoid junction, descend as broad wide bands on anterior and posterior walls of rectum, fuse to form continuous encircling layer of longitudinal muscle along the entire length of rectum. Anteriorly few muscle fibers pass forwards to perineal body as musculus rectourethralis. Two fascimile of smooth muscle may pass from front of second and third coccygeal vertebra to blend with posterior part of rectal longitudinal muscle forming rectococcygeal muscles.

Upper and lower rectum are separated by a horizontal fold consisting of mucosa, circular muscle and part of longitudinal muscle, marked externally by an indentation. Upper rectum is derived from the embryological hind gut, it is surrounded by mesorectum and its contents namely superior rectal artery and its branches, superior rectal vein and tributaries, lymphatic vessels and nodes along superior rectal artery, branches from inferior mesenteric plexus to innervate rectum and loose adipose connective tissue down to the level of levator ani (pelvic floor). Mesorectum is enclosed by mesorectal fascia which is derived from the visceral peritoneum, and is also known as visceral fascia of mesorectum, fascia propria of rectum or presacral wing of hypogastric sheath. Upper rectum generally contains feces and can distend towards the peritoneal cavity⁵. The lower part of rectum is derived from cloaca, is surrounded by condensation of extra peritoneal connective tissue and is generally empty except during defecation. Number of enteric ganglion are much less in rectum and even lesser in anal canal as compared to rest of the colon⁶. Interstitial cells of cajal (ICC) are seen as dense network along submucosal and myenteric borders in rectum⁷.

Anal canal

Anal canal is more like an anteroposterior slit around 2.5 cm to 5 cm long. Anatomically or embryologically the anal canal is shorter while surgically it is assumed to be longer. Proximal end of anatomical anal canal is marked by anal valves and surgical or clinical by distal

Correspondence: Prof. Sneh Agarwal, F-81, Street no.4, Virender Nagar, Janak Puri, New Delhi- 110058, India.

E-mail: doctor.sneh@gmail.com

end of ampullary part of rectum. Upper part of anal canal (proximal 10 mm) is lined by columnar epithelium similar to rectum. Subepithelial tissues here have profuse submucosal arterial and venous plexus. Terminal branches of superior rectal vessels pass downwards towards anal columns. Submucosal veins drain into submucosal rectal venous plexus and also through upper internal anal sphincter into intermuscular venous plexus. Each anal column contains a terminal radicle of the superior rectal artery and vein, these vessels being largest in left lateral, right posterior and right anterior quadrants of wall of anal canal and the subepithelial tissues here expand to form three "anal cushions" which seal the anal canal and help in maintaining continence to flatus and fluid. They also have a role in formation of hemorrhoids. Mid anal canal (next 15 mm) including the anal columns and anal valves at their lower end are lined by stratified or a modified columnar epithelium. Mucosal lining below the anal valves and sinuses (dentate or pectinate line) (next 10 mm) is lined by non keratinized stratified squamous epithelium lacking sweat glands, sebaceous glands and hair follicles. This epithelium is rich in somatic nerve endings. The most distal part of anal canal below the inter sphincteric groove is lined by hair bearing keratinized stratified squamous epithelium continuous with the perianal skin. Submucosa of this region has rich arterial and venous plexus and plenty of connective tissue. The junction between columnar and squamous epithelium is the anal transition zone (ATZ) which is of variable length and position. Sumucosa of ATZ is rich in nerve endings including thermoreceptors. They play a role in continence by providing a highly specialized 'sampling' mechanism by which the contents of lower rectum are identified during periods when upper anal canal relaxes to allow rectal contents to come into contact with upper anal canal epithelium⁸. Anal canal is surrounded by internal and external anal sphincters. (Fig. 2) Internal anal sphincter is a well defined ring of obliquely oriented smooth muscle fibers continuous with the circular muscle of the rectum and terminating at the junction of superficial and subcutaneous parts of EAS. Fibers from conjoint longitudinal coat cross the lower parts of the IAS. Interstitial cells of Cajal (ICC) are located along the periphery of muscle bundles within the circular layer⁶. External anal sphincter is a tube shaped sphincter of striated muscle (Type I, slow twitch fibers) for prolonged contraction which has deep, superficial and subcutaneous parts, now considered to be as a single functional and anatomical entity⁸. Upper most fibers (deep part) blend with fibers of puborectalis, anteriorly decussate with superficial transverse perinei muscle and posteriorly some fibers attach to anococcygeal raphe⁹. Middle fibers (superficial) mainly surround the lower part of internal anal sphincter, attach anteriorly to perineal body and posteriorly to anococcygeal raphe through decussation of some of its fibers anteriorly and posteriorly. Lower fibers (subcutaneous) lie below the level of internal anal sphincter. (Fig. 3)

Nerve supply to the pelvic floor

The anal canal, rectum and pelvic floor are supplied by sympathetic, parasympathetic and somatic fibers⁸. Sympathetic preganglionic fibers originate from lower three thoracic and upper two lumbar spinal segments, synapse in the ganglia associated with lumbar and sacral sympathetic trunk in the aortic, superior and inferior hypogastric plexus. Preganglionic parasympathetic fibers arise from neurons of second to fourth sacral spinal segments. Superior hypogastric plexus lies anterior to aortic bifurcation and sacral promontory, between the two common iliac arteries. It provides branches to uteric/testicular plexus, divides into right and left hypogastric nerves. Hypogastric nerves join preganglionic fibers from ventral rami of second, third

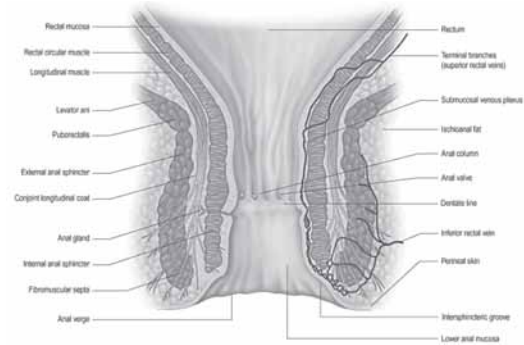


Figure 2: Coronal Section of Anal canal

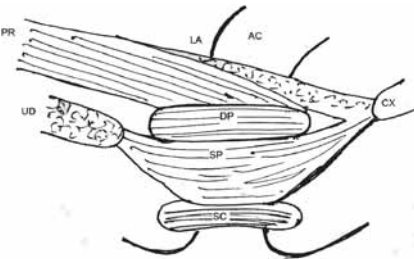


Figure 3- Arrangement of External Anal Sphincter and Pubo rectalis. AC- Anal Canal, LA-Levator ani, PR-Pubo rectalis, DP-Deep part, SP-Superficial part, SC- Subcutaneous part, CX- Coccyx, UD- Urogenital Diaphragm

and fourth sacral nerves to form inferior hypogastric plexus, lying posterior to urinary bladder in the thin extraperitoneal connective tissue lateral to mesorectum. Inferior hypogastric plexus gives rise to middle rectal plexus, vesical plexus, prostatic plexus and uterovaginal plexus.

Rectum and anal canal are supplied by superior, middle and inferior rectal plexuses. Parasympathetic fibers of these synapse with post ganglionic neurons in myenteric plexus of wall of rectum. Also fibers ascend from inferior hypogastric plexus to superior hypogastric and aortic plexus to reach inferior mesenteric plexus which finally innervates descending and sigmoid colon by traveling up along left colonic wall.

Somatic innervation

Rectal and anal responses are represented bilaterally on superior part of motor cortex (brodman area 4) as suggested by cortical mapping with transcranial magnetic stimulation¹⁰.

Motor neurons in Onuf's nucleus, located in the sacral spinal cord innervate external anal and urethral sphincters (striated muscle). Even though these motor neurons supply striated muscle under voluntary control they are smaller than other alpha-motor neurons and resemble autonomic neurons¹¹. Somatic branches arising from Onuf's nucleus travel in pudendal nerve, muscular branches, and in coccygeal plexus. Pudendal nerve branches into inferior rectal, perineal and posterior scrotal or labial nerves. Inferior rectal nerve innervates external anal sphincter and carries sensory input from lower anal canal and skin around the anus. Perineal nerve branches into posterior scrotal (labial) branches and muscular branches. Posterior scrotal branches innervate the skin and muscular branches supply transverse perinei, bulbospongiosus ischiocavernosus, urethral sphincter, anterior part of external anal sphincters and levator ani. Motor supply to EAS by pudendal nerves of the two sides overlaps. Stimulation of right

pudendal nerve causes circumferential contraction of EAS (Sherrington's observation)¹². Tonic activity of EAS, inhibition of EAS during colonic distension and cutaneous reflex are also not affected by sectioning either pudendal nerve. Several workers have shown that puborectalis is innervated from below by pudendal nerve or its inferior rectal or perineal branches and from above by sacral nerves¹³. Pudendal nerve damage may cause dysfunction of puborectalis and EAS both of which are constrictors and may cause fecal incontinence.

Sensory innervation

Colonic distension results in a non descript discomfort and even a non localized pain. Rectal distension is perceived as rectal fullness and a desire to defecate or pass wind. Rectum has mucosal nerve endings and also low threshold slowly adapting mechanoreceptors in the muscularis propria which detect mechanical deformation of mesenteric ganglia and so the tension in the circular and longitudinal muscles of rectum.

The anal canal responds to distension and mechanical shearing stimuli. It is lined by numerous free and organized nerve endings like Meissner's corpuscles, Krauss's end bulbs, Golgi-Mazzoni bodies and genital corpuscles. The nerve endings are exquisitely sensitive to light touch, pain and temperature. Sensory impulses from rectum and anal canal are carried to spinal cord by unmyelinated small C fibers and large A fibers.

IAS tone is chiefly responsible to keep anal canal closed at rest along with EAS, anal mucosal folds, and puborectalis muscle. Anal relaxation induced by rectal distension (recto-anal inhibitory reflex RAIR) is mediated by intrinsic nerves as it is absent in Hirschsprung's disease while preserved in patients with cauda equina lesions or spinal cord transection. Extrinsic nerves may modulate this reflex.

EAS has lesser role in maintaining resting anal tone but contracts to augment anal tone if continence is threatened. This squeeze response may be voluntary or induced by increased intra-abdominal pressure¹⁴. EAS relaxes during defecation. Other striated muscles which show resting activity are puborectalis, external urethral sphincter, cricopharyngeus and the laryngeal abductors and their resting tone depends on monosynaptic reflex drive¹⁵. Puborectalis tone also helps to maintain the resting anorectal angle and contracts during rise in intra-abdominal pressure to reduce anorectal angle preserving continence. It is supplied by pudendal nerve from below pelvic floor and ipsilateral branches arising from sacral plexus above the pelvic floor¹³. Its disruption causes incontinence.

Sacral reflexes

The pelvic floor striated muscles contract reflexly in response to stimulation of perineal skin (somatosomatic reflex) or anal mucosa (viscerosomatic reflex). Cutaneous reflex is elicited by scratching or pricking the perianal skin and involves pudendal nerve and S4 roots.

Sacral reflexes also regulate anal sphincter tone during micturition and IAS tone increases during micturition in humans¹⁶ while EAS is relaxed during micturition in humans.

MECHANISM OF CONTINENCE AND DEFECTION

Fecal continence is maintained by a number of anatomical factors, rectoanal sensation and rectal compliance. Feces is transferred into rectum by colonic propulsive contractions especially after awakening or meals¹⁷. Rectal distension evokes rectal contraction and internal anal sphincter relaxation for evacuation. If defecation is inconvenient

it can be postponed by contraction of EAS until contractions cease and retrograde rectal peristalsis moves stool out of distal rectum so that the sensation of defecation passes off. Initiation of defecation involves relaxation of pelvic floor muscles and EAS so that the pelvic floor descends and anal canal opens. Puborectalis also relaxes during defecation. Abdominal contractions aid expulsion from rectum and mass colonic contractions push more feces down the rectum and entire left colon may be emptied. Integration of sensory input from anal canal to control the activity of anal musculature occurs at different levels of nervous system, i.e. spinal cord, brain stem, thalamus and cortex. This neural activity regulates defecation and other functions like sensing feces separate from rectal gas, fecal consistency, quantity and coordination with other actions of perineal and abdominal muscles.

Pelvic floor disorders traditionally are described as affecting anterior, middle or posterior compartments to be managed by urologists, gynaecologists and colorectal surgeons respectively. Obstetrical trauma predisposes to both pelvic organ prolapse (POP) and fecal incontinence (FI). Anorectal dysfunction in isolation cause FI. Association between fecal and urinary incontinence has observed¹⁸. Surgically it is very important to understand the anatomy of pelvic floor and anorectum especially for managing anal fistulae, preventing nerve injury during surgical dissection and rectal resection. Denonvillier's fascia is an important surgical landmark during anterior rectal resection to preserve the deep parasympathetic nerves and hence prevent impotence. Defecation may be affected after surgical section of pelvic nerves in humans^{19,20}.

BIBLIOGRAPHY

1. Ayoub SF. Anatomy of the external sphincter in man. *Acta Anat (Basel)* 1979;105:25-36.
2. Basoiti GC, Crowell MD, Whitehead WE. Contractile activity of the human colon: lessons from 24 hour studies. *Gut* 1993; 34:129-33.
3. DeLancey JO, Delmas V. Gross anatomy and functional anatomy of the pelvic floor. *Phila delphia*. Elsevier Saunders; 2004.
4. Devroede G, Lamarche J. Functional importance of extrinsic parasympathetic innervation to the distal colon and rectum in man. *Gastroenterology* 1977; 66:273-80.
5. Floyd W, Walls E. Electromyography of the sphincter ani externus in man. *J Physiol* 1953;122:599-609.
6. Holl M. *Handbuch des anatomie*. Jena (Germany): Fischer; 1897.
7. Horiguchi K, Keef KD, Ward SM. Distribution of interstitial cells of cajal in tunica muscularis of the canine rectoanal region. *Am J Physiol Gastrointest Liver Physiol* 2003;284:G756-67.
8. Holstege G, Tan J. Supraspinal control of motoneurons innervating the striated muscles of the pelvic floor including urethral and anal sphincters in the cat. *Brain* 1987;110:1323-44.
9. Kearney R, Sawhney R, Delancy JO. Levator ani muscle anatomy evaluated by origin-insertion pairs. *Obstet Gynecol* 2004;104:168-73.
10. Lawson JO. Pelvic anatomy. I. Pelvic floor muscles. *Ann R Coll Surg Engl* 1974;54:24-52.
11. Melzak J, Porter NH. Studies of the reflex activity of the external sphincter ani in spinal man. *Paraplegia* 1964;1:277-96.
12. Percy JP, Neill ME, Swash M, Parks AG. Electrophysiological study of motor nerve supply of pelvic floor. *Lancet* 1981;1:16-7.
13. Salducci J, Planche D, Naudy B. Physiological role of the internal anal sphincter and the external anal sphincter during micturition. In: Wienbeck M (eds) *Motility of the Digestive Tract*. Raven, New York 1982 pp 513-20.
14. Snooks SJ, Barnes PR, Swash M, Henry MM. Damage to the innervation of pelvic floor musculature in chronic constipation. *Gastroenterology*, 1985;89:977-81.
15. Scott HWJ, Cantrell JR. Colommetrographic studies of the effects of section of the parasympathetic nerves of the colon. *Bull Johns Hopkins Hosp*, 1949;85:310-9.
16. Sandring S (ed). *Gray's Anatomy The Anatomical Basis Of Clinical Practice*. 39th edn. London. Churchill Livingstone: 2008:1198-1210.
17. Turnbull GK, Hamdy S, Aziz Q, Singh KD, Thompson DG. The Cortical topography of human anorectal musculature. *Gastroenterology* 1999;117:32-9.
18. Williams PL, Warwick R (eds). *Splanchnology*. Gray's Anatomy, 36th edn. London. Churchill Livingstone, 1980:1356-64.
19. Weinberg AG. The anorectal myenteric plexus: its relation to hypoganglionosis of the colon. *Am J Clin Pathol* 1970;54:637-42.
20. Wunderlich M, Swash M. The overlapping innervation of the two sides of the external anal sphincter by the pudendal nerves. *Journal of the Neurological Sciences*. 1983;59:97-109.