

Defect in Membranous Ossification of the fossa for Lacrimal Sac and Frontonasal Ostium

TH. NARANBABU SINGH, B.K. DAS, M. MATUM SINGH, CH. RAJENDRA SINGH, M. SHYAMO SINGH, L CHANDRAMANI SINGH

Department of Anatomy, Regional Institute of Medical Sciences, Imphal, Manipur

Abstract: Defect in the fossa for lacrimal sac and nasolacrimal canal was encountered on the left side of a dry female skull age about 40-50yrs. A bony crest was present at the anterior border of lacrimal bone and a thin membranous bone except for a minute canal communiating with nasolacrimal canal closed the bottom of the fossa for lacrimal sac. The left frontal air sinus had neither an ostium nor a frontonasal canal to communicate with the middle meatus of nasal cavity. As the frontal, lacrimal and maxillary bones developed by membranous ossification; these defects may be attributed to the defect in membranous ossification.

Introduction

Fossa for lacrimal sac is formed by the articulation of the frontal process of maxilla and lacrimal bone. It lies between the anterior lacrimal crest in the frontal process of maxilla and posterior lacrimal crest in the lacrimal bone. Below it continues with nasolacrimal canal, which is about 1cm in length and formed by the groove present on the nasal surface of maxilla making 2/3rd of the circumference and the remaining part by the descending part of lacrimal bone and lacrimal process of the inferior nasal concha¹.

Frontal air sinus is situated between the inner and outer tables of the frontal bone. Externally it represents a triangular area posterior to the superciliary arch. The two sinuses are rarely symmetrical and separated by a thin bony septum. Rudimentary at birth, well developed by the age of 7 or 8 yrs, it reaches its full size only after puberty. Each sinus communicates with the middle meatus of the nasal cavity of the corresponding side by frontonasal canal¹.

Case Report

A rare feature of bony stenosis at the junction of fossa for lacrimal sac and nasolacrimal canal on left side due to the developmental defect of left lacrimal and maxillary bone was observed in a skull belonging to a female age about 40-50 yrs. in the Department of Anatomy, Regional Institute of Medical Sciences, Imphal, Manipur. A small canal of about 2mm in diameter communicated the nasolacrimal canal and the fossa for lacrimal sac. The left lacrimal bone articulated in front with the posterior border of frontal process of maxilla and featured a crest from its anterior border. This crest articulated in front with a thin lamellar bone that filled the fossa for lacrimal sac and laterally with the orbital surface of maxilla. The fossa for lacrimal sac was small, but there was a larger fossa between the crest and the posterior lacrimal crest. The part of the bone behind the posterior lacrimal crest was comparatively smaller. There was no lacrimal hamulus (Fig.1).

The left maxilla was normal for all the features except for the thin lamellar bone, which fused with maxilla and filled the fossa for lacrimal sac. The thin lamellar bone fused laterally with the orbital surface, anteriorly and medially with the frontal process and posteriorly with the abnormal crest of lacrimal bone; and formed the floor of the fossa for lacrimal sac. The narrow canal of about 2mm in diameter presented in the lamellar bone communicated the fossa for lacrimal sac and the nasolacrimal canal. The rest of the nasolacrimal canal was normal.

Both the frontal air sinuses were within the normal limit in size, even though the left sinus was comparatively less convoluted. There was no frontonasal canal or ostium on left side. The septum between the two sinuses was incomplete and was not more than a low ridge on the floor at the junction of the two sinuses (Fig.2).

Discussion

Dacryostenosis is 4 times more common in women and it has been attributed to soft tissue infection and tissue fibrosis rather than actual bony stenosis². However; it has been reported that women have significantly smaller dimension in the lower nasolacrimal fossa and this factor may explain the increased prevalence of acquired nasolacrimal duct obstruction in females³. Coincidentally, this skull

Correspondence: Dr. Th. Naranbabu Singh

E-mail : nthounaojam@yahoo.co.in

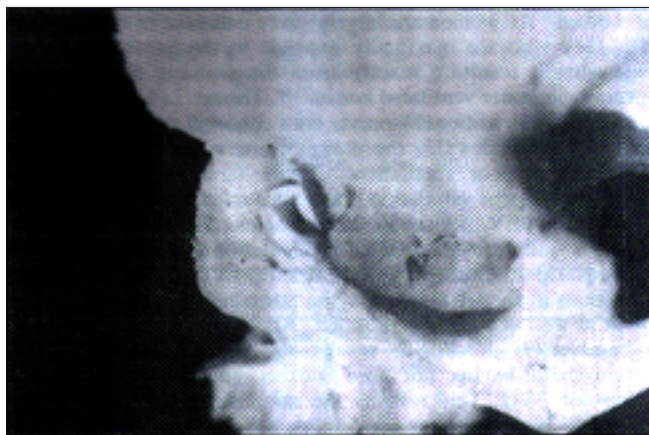


Fig.1 : Shows the medial wall and floor of the orbit. Arrow pointed to the abnormal crest of the lacrimal bone.

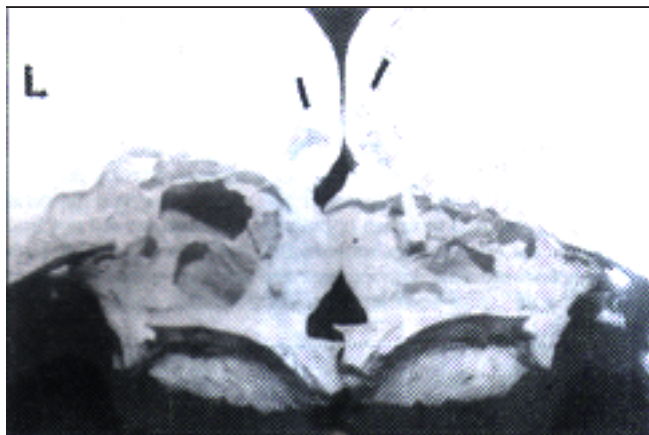


Fig.2 : Hemi-section of the skull showing the two frontal air sinuses (arrowed). The probe passes through the Frontonasal Ostium on the right side, which is absent on left side

also belongs to a female. Report is also available describing smaller nasolacrimal canal as one of the etiologic factors in primary acquired nasolacrimal duct obstruction⁴.

In the present case, the defects are present in the fossa for lacrimal sac as well as the junction of the lower part of fossa for lacrimal sac and upper part of the nasolacrimal canal. These defects are due to the developmental defects of lacrimal and maxillary bones. As both the bones are developed by membranous ossification i.e. lacrimal bone - 12th wk of intrauterine life, maxillary bone - 6 wk of intrauterine life¹, the defects may be attributed to the membranous type of ossification. Several types of developmental defects of lacrimal bone had been reported viz: this bone is frequently

perforated or occasionally represented by several ossicles or completely absent⁵; the hamulus of the lacrimal bone may be separate, double or absent⁶. But the presence of a crest at its anterior border thereby causing the defect of the fossa for lacrimal sac and nasolacrimal canal has not been reported.

Clinically, the individual to whom this skull belongs could have suffered from epiphora. Then the operative measure could have been Dacryocystorhinostomy but not Dacryocystoplasty⁷.

Frontal air sinus develops during 4th month of intrauterine life from (i) anterior ethmoidal cell within the ethmoidal infundibulum; in this situation (comprising 50%) frontal air sinus opens into the ethmoidal infundibulum, (ii) anterior ethmoidal cell - in this situation frontal air sinus opens into the middle meatus of nasal cavity by frontonasal canal (iii) most rarely, from the anterior part of frontal recess of frontal furrow - with only frontonasal ostium without a canal⁸.

In the present case, the right frontal air sinus opens by an ostium, which is absent on left side. From the developmental point of view, these frontal air sinuses are developed from the anterior part of frontal recess of frontal furrow and failed to develop an ostium on left side. As the frontal bone develops by membranous type of ossification¹, this defect also may be attributed to the defective membranous type of ossification.

Clinically, the individual could have suffered from left frontal sinusitis⁹, the treatment of choice could have been trephination or osteotomy or other surgical measures depending upon the severity.

Even though, defects in other membranous bones, foramina or canals could not be observed; all the bones involved in these defects developed by the membranous ossification and these defects may be attributed to this type of ossification defects.

References

1. Soames RW. Skeletal System. In: Williams PL, Bannister LH, Berry MM, Collins P, Dyson M, Dussek JE, Ferguson MWJ, editors. Gray's Anatomy. 38th ed. Edinburgh: Churchill Livingstone 1995;425-736.
2. Linberg JV, McCormick SA. Primary acquired nasolacrimal duct obstruction: A clinicopathological report & biopsy technique. Ophthalmology 1986;93:105.
3. Grossl SA, Sires BS, Lemke BN. An anatomical basis for primary acquired nasolacrimal duct obstruction. Arch Ophthalmol 1997;115(5):655.
4. Janssen AG, Mansour K, Bos JJ, Castelijns JA. Diameter of the bony lacrimal canal: normal values and values related to nasolacrimal duct obstruction: assessment with CT. AJNR Am J Neuroradiol 2001;22(5):845-50.
5. Breathnach AS. Frazer's Anatomy of the Human Skeleton. 6th ed. London: J & A Churchill Ltd 1965;182-238.
6. Bron AJ, Tripathi RC, Tripathi BJ. Wolff's Anatomy of the Eye & Orbit. 8th ed. London: Chapman & Hall Medical 1997.
7. Janssen AG, Mansour K, Bos JJ. Obstructed nasolacrimal duct system in epiphora: long-term results of dacryocystoplasty by means of balloon dilation. Radiology 1997;205(3):791-6.
8. Rice DH. Embryology. In: Donald PJ, Gluckman JL, Rice DH, editors. The Sinuses. New York: Raven Press 1995;15-23.
9. Duvoisin B, Schnyder P. Do abnormalities of the frontonasal duct cause frontal sinusitis? Acta study in 198 patients. AJR Am J Roentgenol 1992;159(6):1295-8.

Miglitol

Miglitol is an alpha-glucosidase inhibitor. The chemical name of miglitol is 3,4,5-piperidinetriol, 1-(2-hydroxyethyl)-2-(hydroxymethyl)-, [2R-(2(alpha), 3(beta), 4(alpha), 5(beta))]. The empirical formula is C₈H₁₇NO₅. Its molecular weight is 207.2

Pharmacodynamics: Miglitol is a 1-deoxynojirimycin derivative which reversibly inhibits intestinal alpha-glucosidase enzymes responsible for the digestion of carbohydrates to absorbable monosaccharides. Its structure resembles that of glucose, and unlike acarbose (a pseudotetracosaccharide alpha-glucosidase inhibitor), it is almost completely absorbed in the upper section of the small intestine. The rank order of its inhibitory activity is sucrase > glucoamylase > isomaltase > lactase > trehalase. Although miglitol delays carbohydrate absorption in healthy volunteers, there are no significant losses of carbohydrates, protein or fat in the faeces and no significant caloric losses.

Miglitol smoothes postprandial glycaemic peaks thereby reducing postprandial peak plasma glucose levels in patients with type 2 diabetes mellitus; miglitol reduces postprandial serum insulin levels or C peptide concentration and serum T9 level after 8 weeks' treatment.

Since miglitol is almost completely absorbed, it has been suggested that it may exert extraintestinal effects on glucose homeostasis. Miglitol significantly reduces the postprandial increase in gastric inhibitory polypeptide in healthy volunteers and patients with type 2 diabetes mellitus. It also increases peptide tyrosine-tyrosine (PYY) and motilin levels. Miglitol, unlike several other compounds with cationic polarity, e.g. biguanides, has no effect on sodium-dependent small intestine transport of organic solutes, such as, hexoses.

Pharmacokinetics: Miglitol 25mg is completely absorbed (100% bioavailability); however, only 50% to 70% of a 100-mg dose is absorbed. At high doses, miglitol absorption is saturable. The mean peak plasma concentrations (C_{max}) following single oral doses of miglitol 25, 50 and 100 mg were 0.78, 1.22 and 1.86mg/L, respectively, and are attained within 2 to 4 hours (T_{max}). The protein binding of miglitol is negligible (< 4.0%). Miglitol has a volume of distribution of 0.18L/kg. Oral miglitol is excreted predominantly unchanged in urine. Thus, following a 25-mg dose, over 95% of the dose is recovered in the urine within 24 hours. At doses above 25mg, less drug is recovered in urine because of incomplete bioavailability. The plasma elimination half-life is approximately 2 hours.

Special population: Renal insufficiency: Patients with a creatinine clearance (Cr Cl) less than 25mL/min had a > 2-fold increase in miglitol plasma levels compared to patients with a CrCl greater than 60mL/min; the dosage was 25mg 3 times daily. Little information is available on the safety of miglitol in patients with creatinine clearance < 25mL/min. **Hepatic insufficiency:** Miglitol pharmacokinetics was not altered in cirrhotic patients relative to healthy control subjects. Since miglitol is not metabolized, no influence of hepatic function on the kinetics of miglitol is expected.

Indications and Usage: Miglitol as monotherapy is indicated as an adjunct to diet and exercise to improve glycaemic control in patients with Type 2 Diabetes Mellitus.

Drug Profile

Contraindications: (1) Diabetic ketoacidosis (2) Chronic intestinal diseases (3) Hypersensitivity to miglitol (4) Inflammatory bowel disease or other conditions which may deteriorate with increased gas formation in the intestine (5) Intestinal obstruction.

Precautions: Hypoglycemia: Because of its mechanism of action, miglitol when administered alone should not cause hypoglycemia in the fasted or postprandial state. Because miglitol given in combination with a sulfonylurea will cause a further lowering of blood glucose, it may increase the hypoglycemic potential of the sulfonylurea. Oral glucose (dextrose), whose absorption is not delayed by miglitol, should be used instead of sucrose (cane sugar) in the treatment of mild-to-moderate hypoglycemia.

Renal Impairment: Patients with a creatinine clearance (CrCl) less than 25 mL/min had a 2-fold increase in miglitol plasma levels compared to patients with a CrCl greater than 60mL/min; the dosage was 25mg 3 times daily.

Carcinogenesis, mutagenesis, impairment of fertility: No evidence of carcinogenesis was observed in animal studies with miglitol. No evidence of mutagenicity was observed in vitro in bacterial mutagenesis (Ames) assay and the eukaryotic forward mutation assay (CHO/HGPRT). No evidence of clastogenicity was observed in vivo in the mouse micronucleus test. In oral fertility studies of miglitol conducted in rats, there was no evidence of reproductive toxicity at doses up to 300 mg/kg/day in male or female rats (~8 times the maximum human exposure based on body surface area).

Miglitol should be used during pregnancy only if the potential benefit justifies the risk to the fetus. It is recommended that miglitol not be administered to a nursing woman. Safety and effectiveness of miglitol in pediatric patients have not been established.

Drug Interactions: Concomitant administration of miglitol with digoxin, propranolol or ranitidine reduced their absorption, and thus the dose of these agents may require adjustment.

Adverse Reactions: The most common adverse events in miglitol-treated patients involve the gastrointestinal system and include flatulence, abdominal pain and diarrhoea. Symptoms are usually mild to moderate in intensity, dose dependent, occur at the onset of treatment, decline with time and resolve promptly on discontinuation of the drug or with dosage adjustment. Compared with placebo, miglitol showed no significant effects on renal, cardiovascular, respiratory or haematological functions in long term clinical studies (6 months to 1 year).

Dosage and Administration: Adult dose: There is no fixed dosage regimen for miglitol. The maximum recommended daily dosage is 100mg 3 times daily, with treatment initiated at a dosage of 25mg 3 times daily and gradually increased. The recommended maintenance dose is 50mg 3 times daily. No dosage adjustments are required in elderly patients, in those with hepatic impairment or those with mild to moderate renal insufficiency. Miglitol is not recommended in patients with significant renal impairment (serum creatinine > 2mg/dL).