

RADIOLOGICAL INVESTIGATIONS IN UROLITHIASIS

Sapna Singh, Veena Chowdhury

Department of Radiology, Maulana Azad Medical College & Associated Lok Nayak and G.B. Pant Hospital,
New Delhi- 110002, India

Abstract : Radiological investigations play a key role in diagnostic work up of urolithiasis . While conventional investigations like X ray KUB, USG and IVP are still considered essential for diagnosis ,newer modalities like CT Urography and MR Urography have increased the sensitivity and specificity of diagnostic work up. Decision on the appropriate radiological investigation is usually based on several factors which include the pretest probability of the disease, the prevalence of the disease, the accuracy of the test, the potential risks of the test and the discomfort it causes to the patients & the cost; the ideal test should improve the patient's treatment by providing answers to the clinical questions.

Acute flank pain or acute renal colic, secondary to urolithiasis, is a common problem in patients presenting to the emergency unit of a hospital and majority are between 30 and 60 years of age. Men are affected three times more often than women¹.

X-RAY KUB

A plain film of the abdomen/X-ray KUB is usually the first radiological investigation performed in these patients. The diagnostic accuracy of the plain film for the detection of urinary tract calculus depends on the chemical composition of the stone, its size, location, overlying bowel gas shadows and technical quality of the film. Approximately 90 percent of urinary stones contain calcium (calcium oxalate, magnesium ammonium phosphate) and 10 percent are calcium free (uric acid, cystine and xanthine)². Although 90% of urinary tract calculi are radio opaque, only 59% of urinary stones are visible on abdominal radiographs³.

Bowel gas or extrarenal calcification may lead to calculi being overlooked or obscured. In addition the ribs, transverse processes and the sacrum may obscure urinary tract calculi. The cortical margin of the lateral edge of the transverse process may mimic a ureteral calculus and can be particularly confusing. Common calcifications in the abdomen need to be distinguished from renal calculi. Gallstones need to be distinguished from renal calculi. Gallstones are large with a characteristic ovoid shape. However, renal calculi in a calyceal diverticulum or an obstructed portion of the collecting system may mimic gallstones⁴. In such cases a lateral or oblique radiograph of the abdomen helps. On the lateral view, the gallstones lie in an anterior location while renal calculi remain in a more posterior location (Fig. 1 A & B). Pancreatic calcification of chronic pancreatitis often involves the entire gland and this helps to distinguish these calcifications from renal stones. Calcification of the costal cartilage of the ribs and arterial calcification is usually linear which helps to separate them from renal stones. Mesenteric nodes have a characteristic mottled appearance. The calcifications most often confused with ureteric calculi are phleboliths. Typically phleboliths are rounded have a central lucency and are seen in the true pelvis often below the distal ureter.

RADIODENSITY OF THE VARIOUS TYPES OF CALCULI ON KUB

A careful examination of the shape and density of the calculi may provide a clue to the chemical composition of the calculus⁵.

Calcium Stones

Calcium oxalate and calcium phosphate stones crystallize when the

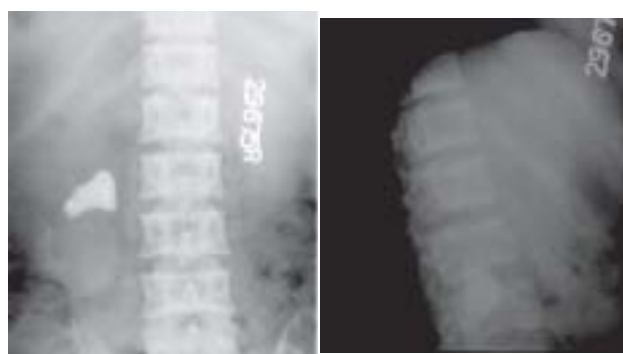


Fig. 1 A & B: Plain abdominal radiograph AP view(A) showing a densely calcified left renal stone and the lateral film(B) showing the calculus to lie posteriorly overlying the spine.

product of the two ions exceeds the solubility of the product. Hypercalcemia is a common cause of hypercalciuria and may result from a variety of metabolic processes. Hypercalciuria may be idiopathic and this is probably the most common cause of nephrolithiasis. Pure calcium phosphate and calcium monohydrate stones are the densest per volume of stone. (Fig. 2A & B) This fact is important since these stones are less amenable to ESWL. Calcium oxalate dihydrate stones are considered fragile and have a spiculated or mulberry / dotted configuration.

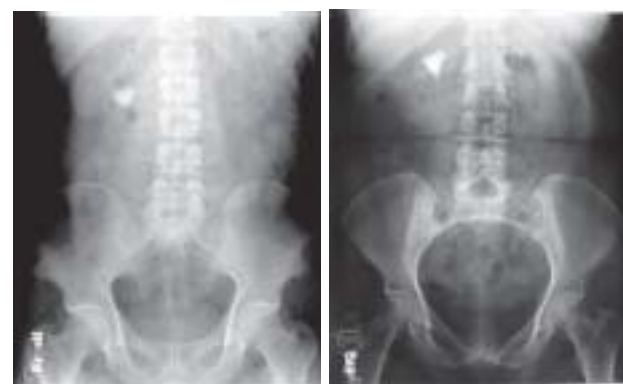

Fig. 2A & B: Plain abdominal radiographs showing densely calcified right renal stones (different patients) suggesting calcium containing stones.

Correspondence: Prof. Veena Chowdhury, Director, Professor & Head of Department, Maulana Azad Medical College & Associated Lok Nayak and G.B. Pant Hospital, New Delhi- 110002, India