

especially in high demand young individuals.

CONCLUSION

It is concluded that non-operative treatment remains the gold standard treatment for undisplaced and minimally displaced fractures. For displaced fractures in highly active young population arthroscopic fixation with early rehabilitation and early return to pre-injury status can be done. The above procedure can be done with ease by orthopaedic surgeons doing routine shoulder arthroscopy; it has predictable and reproducible outcomes. This procedure can be done at a centre with basic shoulder arthroscopic equipment.

Ludwig Angina: A Case Report.

B. Mallikarjunappa, Shama M.S., Subrat Gupta

Adichunchanagiri Institute of Medical Science

B.G. Nagara Nagamangala, Taluk Mandya District, Karnataka, India

Abstract : Ludwig angina is a rapidly progressing submaxillary, submandibular, and sublingual necrotizing cellulitis of the floor of the mouth that can have lethal consequences due to airway obstruction. Patients with deep neck infections present challenging airways for the consultants. Patients with Ludwig’s angina may die as a result of the inability to effectively manage the airway.

INTRODUCTION

Ludwig’s angina is defined as a potentially lethal, rapidly spreading cellulitis, involving the sublingual and submandibular spaces, and is manifested by a brownish suprahoid induration, tender swelling in the floor of the mouth, and elevation and posterior displacement of the tongue.

Ludwig’s angina and deep neck infections are potentially lethal entities because of their tendency to cause edema, distortion, and obstruction of the airway and may arise as a consequence of airway management mishaps. Various aerobic and anaerobic microorganisms, and less often fungi, have been implicated to cause Ludwig angina, including oral flora such as streptococci and staphylococci. Early recognition and the use of parenteral antibiotics can prevent mortality and morbidity.

We report a case who presented with respiratory distress, difficulty in swallowing progressive swelling of the neck in a diabetic pt

CASE REPORT

52 year old male diabetic pt ref for USG neck with gross swelling of the neck. USG revealed gross subcutaneous oedema loss of soft planes and hypo-echoic areas in the submandibular and submental area. Plain x-ray neck shows air pocket at submandibular area .

CECT shows multiple ill defined intercommunicating infective collection occupying neck spaces B/L predominantly involving left parapharyngeal space, B/L submandibular & sublingual space with rest of imaging feature. Multiple enlarged enhancing lymph nodes in B/L internal jugular & submandibular region.

DISCUSSION

Ludwig’s angina was first detailed by Wilhelm Frederick Von Ludwig in 1836.

Ludwig’s Angina “Angere” Latin word throttling (1939, Grodinsky) occur bilaterally in more than one space with production of gangrenous serosanguinous infiltration with or without pus. It involve connective tissues fascia and muscle but not glandular structures.

Correspondence: Dr. B. Mallikarjunappa, Department of Radio-Diagnosis, Adichunchanagiri Institute of Medical Sciences, Bellur, Karnataka, India e-mail: drmallikarjunappa@gmail.com

REFERENCES

- 1.) Nordqvist A, Petersson C. The incidence of fractures of the clavicle. *ClinOrthop.* 1994;300:127-32.
- 2.) Robinson CM. Fractures of the clavicle in the adult. *Epidemiology and classification. J Bone Joint Surg Br.* 1998;80:476-84.
- 3.) Neer CS 2nd. Nonunion of the clavicle. *JAMA.* 1960;172:1006-11.
- 4.) Edwards DJ, Kavanagh TG, Flannery MC. Fractures of the distal clavicle: a case for fixation. *Injury.* 1992;23:44-6.
- 5.) Hessmann M, Kirchner R, Baumgaertel F, Gehling H, Gotzen L. Treatment of unstable distal clavicular fractures with and without lesions of the acromioclavicular joint. *Injury.* 1996;27:47-52.
- 6.) Jenkinson C, Layte R, Wright L, Coulter A. The UK SF-36: an analysis and interpretation manual. Oxford: Health Services Research Unit; 1996.
- 7.) Kona J, Bosse MJ, Staeheli JW, Rosseau RL. Type II distal clavicle fractures: a retrospective review of surgical treatment. *J Orthop Trauma.* 1990.



Fig .1. Photograph showing submandibular, submental swelling

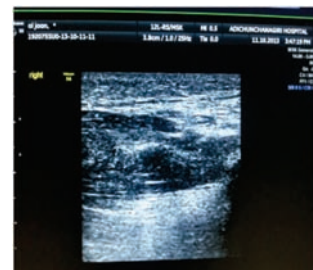


Fig 2.USG showing hypoechoic area in the submandibular region - abscess

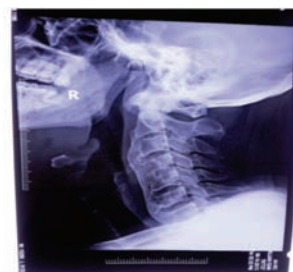

Fig 3. Lat view x-ray neck showing the air in the submandibular region with thickening of soft tissue, and paravertebral Soft tissue.

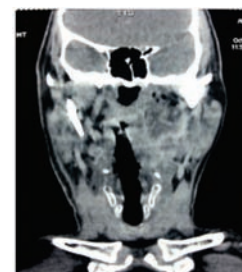


Fig 4. Contrast CT Axial-coronal scan showing ill defined intercommunicating infection collection occupying neck spaces

Spread by continuity, not by Lymphatics⁸.

Ludwig’s angina is odontogenic in origin in 90% of cases. Various other causes are oral lacerations, mandible fracture and infection of oral malignant tumor. Recent infection or extraction of lower 2nd or 3rd molar are the most common cause for Ludwig’s angina as their roots extend below the mylohyoid line of the mandible.

Diagnostic features are rapidly progressive cellulitis; an abscess develops along fascial planes with direct extension; does not involve

lymphatic spread does or not involve submandibular gland or lymph nodes, Involve both sublingual and submaxillary spaces and is usually bilateral. The patient present in the clinical manifestations is severe dysphagia, cervical tenderness, swelling, limited range of motion dysphonia sitting upright, drooling and tachypnea. Trismus, result of inflammation and edema of the masseter space. Extension to lateral pharyngeal retropharyngeal and prevertebral spaces invariably produces severe trismus. Tense brawny induration of involved spaces with little to no fluctuance.

The principle role of imaging is to evaluate the patency of airway, document the presence of underlying dental infection, and look for possibly drainable neck abscesses. Complications such as mandibular osteomyelitis and infection of carotid sheath structures should not be overlooked. Contrast-enhanced CT hence is the study of choice.

Imaging Soft-tissue x-ray of neck may demonstrate swelling of affected area, airway narrowing and gas collection • CT and MRI are the imaging modality of choice • Ultrasound is useful in diagnosing abscess and edema and aid in drainage procedure.

Predisposing conditions include, diabetes, neutropenia, alcoholism, aplastic anemia, glomerulonephritis, dermatomyositis, systemic lupus erythematosus.

Differential diagnosis includes angioneurotic edema, cellulitis, lingual carcinoma, lymphadenitis, peritonsillar abscess, salivary gland abscess sublingual hematoma

Management: Adequate airway management. If no respiratory difficulties, Maintain in sitting position, Continuous monitoring, Must be prepared to intubate Airway complications must be anticipate as concurring supraglottic edema, nuchalrigidity, trismus may interfere with securing the airway.

Antibiotic therapy must be designed to cover both anaerobes and

Staphylococcus aureus. Penicillin with or without metronidazole is the first line therapy. Clindamycin, metronidazole alone, or amoxicillin/clavulanic acid are also considered highly effective.

Surgical therapy is usually reserved for cases of medical treatment failure. Certainly, if the infection is suppurative, with an area of fluctuance, surgical drainage is indicated. One African center, reports the avoidance of tracheostomy with early surgical drainage under local anesthesia

CONCLUSION

Ludwig's angina is rare and sometimes fatal. Morbidity & mortality primarily result from airway compromise from swelling. Etiology usually involves an odontogenic infection. Streptococci are the most common bacteria associated with Ludwig's angina. Early recognition, prompt airway control, and antibiotic administration are the keys to optimum outcome. Early consultation with an anaesthesiologist and an Otorhinolaryngologist are strongly encouraged.

ACKNOWLEDGEMENTS

The authors acknowledge and thank our supt, Dr. Manohar & principal Dr, Shivaramu for granting us permission to publish the case report.

BIBLIOGRAPHY

- 1.) Ludwig's angina and airway considerations: a case report Anand H Kulkarni¹, Swarupa D Pai², Basant Bhattarai³, Sumesh T Rao and M Ambareesha,
- 2.) Case Report 17 ADVANCED LUDWIG'S ANGINA - A CASE REPORT Luqman Muhamed MI Indian Journal of Medical Case Reports ISSN: 2319-3832(Online) An Online International Journal Available at <http://www.cibtech.org/jcr.htm> 2013 Vol.2 (3) July-September, pp.17-19/ Muhamed et al.
- 3.) Ludwig's Angina: A Rare Case Report S Vijay Parthiban*, R Sathish Muthukumar**, M Alagappan³, M Karthiar⁴ Indian Journal of Multidisciplinary Dentistry, Vol. 2, Issue 3, May-July 2012

LITERATURE REVIEW

METABOLIC SYNDROME IN PATIENTS WITH SYSTEMIC LUPUS ERYTHEMATOSUS FROM SOUTH INDIA

Balachandra S. Bhat, Molly Mary Thabab, Vir Singh Negi, etal Indian Journal of Rheumatology, Vol. 10, Issue 4, 189-195

Aims: To find the prevalence of metabolic syndrome in systemic lupus erythematosus (SLE) compared to controls and to identify association of metabolic syndrome with SLE disease activity and damage. A total of 82 SLE and 82 healthy controls were studied. Metabolic syndrome was defined by National Cholesterol Education Program-Adult Treatment Panel III (NCEP ATP III), consensus definition for Asian Indian Adults and World Health Organisation (WHO) 1999 definition, and associations with lupus characteristics, disease activity, and damage were examined. Insulin resistance (IR) was estimated using the homeostasis model assessment for IR (HOMA-IR). Metabolic syndrome was present in 24.39% SLE and 12.19% controls ($p < 0.04$) by NCEP ATP III criteria; 29.26% SLE and 19.51% controls ($p = 0.14$) by consensus definition for Asian Indians; 18.2% SLE and 7.31% controls ($p < 0.035$) by WHO 1999 criteria. Hypertension and hypertriglyceridemia were more frequent in SLE than in controls. Mean body mass index, diastolic and systolic blood pressure, triglycerides, and total cholesterol were higher in SLE than in controls. HOMA-IR (median, range) was 1.31 (0.06–9.32) and 1.55 (0.01–7.92), $p = 0.09$ in SLE and controls, respectively. There was no association of metabolic syndrome with disease activity/damage and prednisolone use. SLE patients with metabolic syndrome had a significantly longer duration of disease compared to patients without metabolic syndrome. Conclusion: South Indian SLE patients have higher prevalence of NCEP ATP III and WHO defined metabolic syndrome compared to healthy controls. SLE patients have an altered lipid profile, but there was no IR and no association of metabolic syndrome with disease activity or damage.

LITERATURE REVIEW

IL-17 IS A KEY CYTOKINE CORRELATING WITH DISEASE ACTIVITY AND CLINICAL PRESENTATION OF SYSTEMIC LUPUS ERYTHEMATOSUS

Sahar M. Abdel Galil, Nillie Ezzeldin, Dina Said, Mohamed El-Boshy Indian Journal of Rheumatology, Vol. 10, Issue 4 196-201

Aims: To determine the role of IL-17 cytokine in systemic lupus erythematosus (SLE) patients and its association with clinical presentation of the disease and disease activity. 72 SLE patients and 70 healthy age and sex matched controls were included in the study. SLE disease activity was assessed in all patients with SLE disease activity index (SLEDAI-2K) scores. Plasma levels of IL-6, and IL-17 were measured by enzyme-linked immunosorbent assay and correlated their levels with clinical manifestations of the disease and SLEDAI-2K. Plasma levels of IL-6 and IL-17 were significantly elevated in SLE patients than in control subjects (13.98 ± 6.95 versus 7.47 ± 1.23 pg/mL) and (19.47 ± 10.21 versus 9.93 ± 1.89 pg/mL), respectively. IL-6 and IL-17 were positively correlated with SLEDAI-2K scores ($r = 0.684$ at $P < 0.001$, $r = 0.322$ at $P = 0.006$), and lupus nephritis ($r = 0.364$ at $P = 0.002$, $r = 0.474$ at $P < 0.001$) respectively; similarly, the IL-17/IL-6 ratio was positively correlated with SLEDAI-2K ($r = 0.243$ at $P = 0.039$). Also, the level of both cytokines was positively correlated to each other during periods of disease activity ($r = 0.755$, $P < 0.001$) as well as during remission ($r = 0.384$, $P = 0.040$). Conclusion: Over-expression of IL-17 correlates with disease activity of SLE. A longitudinal study in a larger cohort of SLE patients can help validate the results.