

ROLE OF CORRECTIVE SERIAL PLASTER CAST APPLICATION IN MANAGEMENT OF CTEV PRESENTING WITH MODERATE DELAY

J.P.S. Walia B.S. Brar, Parveen Garg

Department of orthopedics, Govt. Medical College and hospital, Patiala, Punjab, India

Abstract: The present study aims at studying the role of corrective serial POP cast in the management of CTEV cases presenting with moderate delay. 30 patients with type II CTEV deformity were included in the study and evaluated clinically according to the grading in the oxford clubfoot programme before serial casting was begun. Radiographs of the foot were taken before casting was begun. Six corrective serial casts were applied at 15 days intervals. After a follow up period of 3 months, all clinical and radiological tests conducted at the start of the study were repeated. The degree of correction in each foot and residual deformity were noted. It was found that the more severe the initial deformity, the more resistant it was to conservative treatment particularly in case of equines. But this did not hold true for adduction deformity, which was corrected in most cases by casting irrespective of the initial severity.

INTRODUCTION

Congenital clubfoot is one of the most common foot disorders with an incidence of approximately 1 to 1.4 case per 1000 live births. The term talipes equinovarus is derived from Latin: talipes, a combination of the words talus (ankle) and pes (foot); equinus, meaning horseklike" (the heel in plantar flexion at ankle joint); and varus, meaning inverted at subtalar joint and adducted at midtarsal joint as reported by Lehman¹. Boys are affected twice as girls as reported by Wynne Davies².

Clinical grading of main deformity of clubfoot done by Tibrewal et al³ and oxford clubfoot programme⁴.

CTEV is a highly dynamic disorder, which may vary from a relatively mild variant that is amenable to simple conservative treatment to a highly rigid type, which is almost resistant to all treatments available. Numerous studies have been done on the clubfoot since it was first described by Hippocrates⁵.

There are many advocated approaches to the treatment of clubfoot. Most researches agree that a period of casting can correct some clubfeet. In classical article on the treatment of congenital clubfoot by Kite JH⁶, a strong plea was made for conservative treatment of congenital clubfoot. The literature revealed significant gray areas in the field of treatment determination in type 2

CTEV. No well-defined criteria exist for cases that present moderately late, or have improper previous treatment.

Most centres internationally advocated non-operative treatment in cases <1 month. However the scene in the underdeveloped countries is unique in the sense that treatment is often delayed till as late as 6 months. In this aspect it was thought worthwhile to study the efficacy of serial POP casting in feet with isolated CTEV, and to try and identify factors that will lead to failure.

MATERIALS & METHODS

30 feet with type – 2 CTEV were included in this study. All the children were below 6 months and more that 1 month. No child had any associated medical/surgical illness.

A thorough clinical examination to assess the condition of skin, extent of deformity, muscle bulk, joint movement and neurovascular status of the foot was done along with clinical grading of main deformities of clubfoot.

Radiographs of the foot were taken before casting began by placing the foot in a position of maximum correction. Antero-posterior and lateral views were taken and the following angles were measured. Normal range of these angles are:-

Talocalcaneal angle (TC)	AP 30° - 50° LAT 25° - 50°
Talo-first metatarsal angle (TMT):	AP 5° - 15°
Talo-tibial angle (TT):	Stress lateral 62° - 85°
Tibio calcaneal angle (TiC):	Stress lateral 50° - 75°

METHOD OF POP APPLICATION

The skin was painted with an adherent such as tincture of benzoin. The surgeon applied the cotton in reverse direction pulling the foot into abduction. In a right clubfoot cast the surgeons left hand mainly the first index finger, pull the heel out of inversion, the pulp of the left thumb fits in the sinus tarsi and hold the head of the talus medially. The thumb of the right hand pushes on the first metatarsal to push the foot out of adducts and also everts the forefoot. Once the cast is applied the patient parents will be explained clearly about plaster care and post cast complications. After 15 days the cast was removed. The foot was washed and thoroughly cleaned; degree of correction was assessed clinically and noted. The foot was the remanipulated to the maximum correctable position and cast re-Applied. Six serial casts were applied at 15 days intervals. After a follow-up period of 3 months, all clinical and radiological tests were repeated. The degree of correction in each foot and residul deforming were noted.

CLINICAL ASSESSMENT

Tables 1,2,3&4 analyse the clinical assessment (pre & post operative), grading of equines and various deformities in the subjects studied.

Table 1 :Age and sex distribution.

Age (months)	Male	female	Total
1-2	3	2	5
2-3	8	3	11
3-4	6	3	9
4-5	1	0	1
Total	18	8	26

Correspondence : Prof. J.P.S Walia

70-E, Police Lines, Patiala - 147001

Table 2: Pre & post POP assessment of equinus deformity

Equinus deformity	Post – POP equinus deformity			
	Grade – 0	Grade – I	Grade – II	Grade – III
Grade – III	0(0%)	0(0%)	6(30%)	14(70%)
Grade – II	6(60%)	1(10%)	3(30%)	0(0%)
Grade – I	6(20%)	1(3%)	9(30%)	14(47%)

Table 3: Pre & post POP assessment of varus deformity

Varus deformity	Post – POP varus deformity			
	Grade – 0	Grade – I	Grade – II	Grade – III
Grade – III	0(0%)	8(32%)	14(56%)	3(12%)
Grade – II	2(40%)	3(60%)	0(0%)	0(0%)
Grade – I	2(7%)	11(37%)	14(46%)	3(10%)

Table 4 : Pre & post POP assessment of adduction deformity

Adduction deformity	Post – POP adduction deformity			
	Grade – 0	Grade – I	Grade – II	Grade – III
Grade – III	14(78%)	4(22%)	0(0%)	0(0%)
Grade – II	10(84%)	2(16%)	0(0%)	0(0%)
Grade – I	24(80%)	6(20%)	0(0%)	0(0%)

It was seen that the equinus deformity persisted in most cases and was most resistant to treatment. While varus and adduction deformities including hindfoot mobility improved significantly with POP casting; adduction being most amenable to POP casting treatment.

Radiological Assessment: The measurements of various angles on radiography before casting are depicted in Table – 5, the results after POP casting are depicted in Table – 6.

Table: 5 Pre-casting radiological assessment of foot

Measuring angle	Number of cases in relation to angle (in°)								
	0-10	11-20	21-40*	41-80	81-90	91-110	111-130	131-150	Total
TC angle (AP)	12	10	8						30
TMT angle (AP)				3	10	5			30
TC angle (Lat.)	13	15	2						30
TiC angle (Lat.)					3	11	16		30
TT angle (Lat.)					7	9	10		30

*31-40 : NIL; 41-50 : 30 (TMT-AP); >150: 4 (TT ANGLE)

Table: 6 Post-casting radiological assessment of foot

Measuring angle	Number of cases in relation to angle (in°)									Total
	0-10	11-20	21-40	41-80*	81-90	91-110	111-130	131-150		
TC angle (AP)	3	10	16	1*					30	
TMT angle (AP)	18	2	10						30	
TC angle (Lat.)	3	14	13						30	
TiC angle (Lat.)				6	1	6	3	12	30	
TT angle (Lat.)					6	3	12	10	30	

*40-50 : NIL; >150: 2 ; TT =2

It was seen that change in talocalcaneal angle (AP), talo-first metatarsal angle and talocalcaneal (Lat) angle was significant. In case of tibio-calcaneal and talo-tibial angles there was not significant changes in the angles.

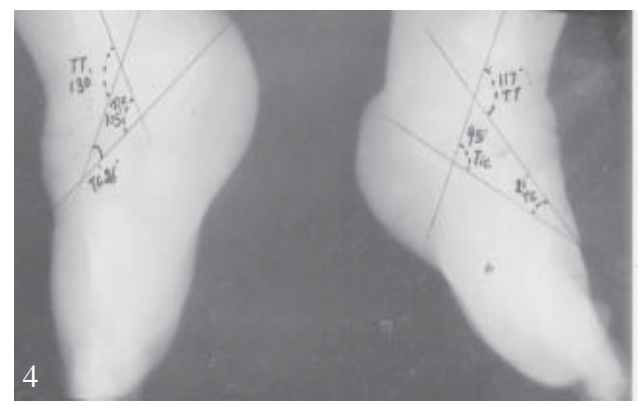
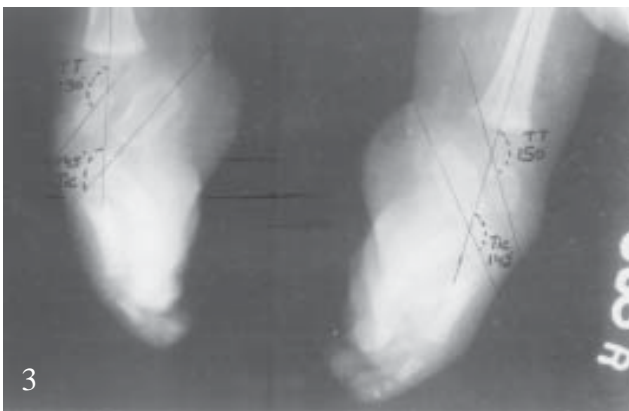
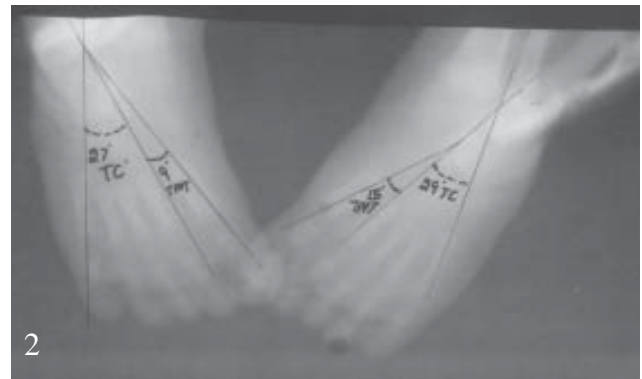
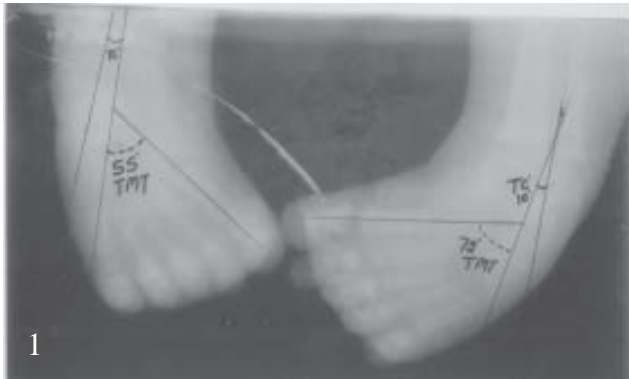DISCUSSION

The basis upon which nonoperative techniques rest is the correction of the deformity through the production of plastic (permanent) deformation (lengthening) of the shortened ligaments and tendons in the involved foot. Serial manipulation and cast immobilisation relies on the viscoelastic nature of connective tissue to produce plastic deformation through a process known as stress relaxation. Deformity is corrected as much as possible with gentle stretching, which places the shortened tissues under tension. As the foot is held by the maximally corrected position in the cast, the tension in the shortened tissues decreases over time. When the tension decreases sufficiently, more correction can be obtained by repeating the process⁷.

After analysis of the results it was seen in our study that equinus deformity was most resistant to casting treatment. Out of 30 feet, with Grade – III equinus deformity, 14 feet (70%) persisted as Grade – III and 6 feet (30%) improved to Grade – II. Out of 10 feet with Grade – II equinus deformity 3 feet (30%) persisted as Grade – II, one foot (10%) improved to Grade – I and in 6 feet (60%) the equinus was fully corrected. Grade – III equinus deformity when compared to Grade – II had less chance of correction. So for complete, tenotomy of Z – Plasty lengthening of tight tendoachilles is required. In the feet treated by casting. Simons⁸ stated that the equinus is usually the last and most difficult deformity to correct with conservative treatment, Which is also consistent with our findings. In case of varus deformity out of the 25 feet with Grade – III varus deformity 3 feet remained at Grade – III, 14 feet with Grade – II and 8 feet improved to Grade – I varus after casting. Out of 5 feet with Grade – II varus deformity 3 feet improved to Grade – I and in remaining 2 (40%) feet the deformity was fully corrected. It was seen that the severity of varus did not have a significant influence on the outcome. The talocalcaneal (AP) and talocalcaneal (Lat) indicative of varus improved after treatment. The degree of correction of varus deformity was proportional to the improvement in hindfoot mobility.

In our experience forefoot adduction deformity was most amenable to casting and correction was achieved in most of the cases. The talo-first metatarsal (AP) angle (indicative of adduction deformity) before and after casting improved and the improvement was significant.

There was a positive co-relating b/w clinical assessment & radiological



Photographs (1) , (2) , (3) ,(4) are of case A presenting with B/L CTEV. Photograph (1) Photograph of X- ray (AP View) both feet before POP application It shows Talocalcaneal (TC) and Talo-first Metatarsal (TMT) angles of both feet. Rt. Side Lt Side
TC Angle – 00 TC Angle - 100

scores. Other studies also emphasized that radiological score is an objective representation of structure and function of the foot and can be used to distinguish the foot which will be easy to treat from those that will be difficult as stated by Bansal et al ⁹.

None of the previous studies have tried to focus clearly on the role of serial corrective plaster cast application in type 2 rigid CTEV. Researchers like Ikeda¹⁰ stress that conservative methods can achieve good outcome in the treatment of idiopathic clubfoot and criticises surgical intervention; as observed by other workers ^{6,11,12,13}.

In our study we found that the more severe the initial deformity, the more resistant it was to conservative treatment particularly in case of equinus. But this did not hold true for adduction deformity, which was corrected in most cases by casting irrespective of the initial severity.

CONCLUSION

Serial POP correction is a good option in the treatment of type II CTEV, in cases presenting with moderate delay.

BIBLIOGRAPHY

1. Lehman, Wallace B. The clubfoot. Phil J.B. Lippin Cott 1980; 1 – 5.
2. Wynne Davies R. Family studies and the cause of congenital clubfoot. J Bone Joint Surg 1964; 46(B) 445 – 453.
3. Tibrewal SB, Benson MKD, Howard C, Fuller DJ. The Oxford Clubfoot Programme. J Bone Joint Surg 1992; 74 (B): 528 – 33.
4. Fuller, D.J. (1984) Oxford Clubfoot Programme; Proceeding. Journal of Bone and Joint Surgery 66B, 142-43.
5. Carroll NC. Clubfoot: What have we learned in the last quarter century. J Pediatr Orthop 1997; 17: 1 – 2.
6. Kite JH. Nonoperative treatment of congenital clubfoot. Clin Orthop 1972; 84: 29 - 38.
7. Cummings RJ, Davidson RS, Armstrong DF, Lehman WB. Congenital clubfoot. J Bone Joint Surg Am 2002; 84(2): 290 – 308.
8. Simon GW. Analytical radiography of clubfoot. J. Bone Joint Surg 1977; 59-B: 485-489.
9. Bansal VP, Daniel J and Rai J. Radiological score in the assessment of clubfoot. International Orthopaedics 1988; 12: 181 – 185.
10. Ikeda K. Conservative treatment of idiopathic clubfoot. J Pediatr Orthop 1992; 12: 217 – 223.
11. Blumenfeld I, Kaplan N and Hicks EO. The conservative treatment of congenital talipes equinovarus. J Bone Joint Surg 1946; 28: 765-776.
12. Kuhlmann RF. Conservative management of congenital clubfoot deformity. Am J Dis Child 1954; 87: 440 – 447.
13. Ponseti IV. Clubfoot management. J Pediatr Orthop 2000; 20: 699 – 700.

CONFERENCE NEWS

16th Annual Conference of Indian Society of Otology – ISOCON 2007 will be from 16th to 18th November, 2007. The venue will be Taj Krishna, Hyderabad. **Guest Speakers:** Prof.Mario Sanna from Italy; Dr.Matthew Yung from U.K.; and Dr.Jahnke Klaus from Germany. The conference will be one day lectures, panel discussion and oration, two days of live surgeries, instructional courses and ENT quiz.

Contact : Dr. T.V. Krishna Rao, Organising Chairman, ISOCON 2007 “UMA KRISHNA”, 5-9-30/1/27AB, Basheer Bagh Palace Hyderabad – 500 063. Tel : 040-23222255; e-mail: dr Rao@mmdsofttech.com